

<http://dx.doi.org/10.35630/2199-885X/2020/10/37>

STRUCTURAL ARRANGEMENT OF THE TEMPOROMANDIBULAR JOINT IN VIEW OF THE CONSTITUTIONAL ANATOMY

Dmitry Domyuk^{1✉}, Sergey Dmitrienko²,
Stanislav Domyuk³, Yuri Harutyunyan¹

¹ Department of General Practice Dentistry and Child Dentistry, Stavropol State Medical University, Stavropol, Russia

² Department of Dentistry, Volgograd State Medical University, Volgograd

³ North Caucasus Federal University, Stavropol, Russia

✉ domyukda@mail.ru

ABSTRACT — Based on the data obtained through panoramic roentgenograms, cone beam computed tomograms from 297 people featuring various somatotypes, orthognathic bite, and no sign of dentoalveolar pathology, we identified the morphometric parameters for the temporal bone mandibular (articular) fossa, and for the lower jaw head, followed with calculation of index values and the temporomandibular joint temporal congruent index. Depending on the linear and index values of the articular fossa, the patients were diagnosed with a brachio-, meso- and dolichotemporal type of the temporomandibular joint. The articular fossa index value ($48.59 \pm 1.82\%$) of the mesotemporal type indicates a double prevalence of the antero-posterior parameter over the vertical one; a decrease in the index down to $35.29 \pm 1.74\%$ for the brachytemporal type means a more significant reduction in the articular fossa vertical size (*long* and *low*); an increase in the index up to $56.65 \pm 2.12\%$ of the dolichotemporal type points at an increase in the articular fossa vertical parameters (*short* and *high*). Regardless of the articular fossa type, in case of the orthognathic bite, the lower jaw head has been proven to occupy no more than 56.33% of the temporomandibular joint volume, evidence to that being the congruency index value. Analysis of constitutional types suggests the predominance of patients with the asthenic type of physique ($56.6 \pm 4.3\%$) over those with a normosthenic ($27.3\% + 2.9\%$) and a hypersthenic ones ($16.1 \pm 2.3\%$). Further study of the issues related to the temporomandibular joint individual variability in people with different types of body constitution will allow customizing the approach to therapy & prevention measures, as well as it would make help predict the treatment outcomes for patients with muscle & joint dysfunction.

KEYWORDS — temporomandibular joint, individual typological variability, constitutional anatomy, cone beam computed tomography, physiological occlusion.

INTRODUCTION

Unresolved issues involving the structural arrangement (morphology, topography) and the temporomandibular joint (TMJ) functions, the spatial location in the skull and the relationship with other areas of the craniofacial complex, as well as the specific features of pathology diagnostics — all these are within the research and clinical focus. The data published on the issue is ambiguous, which is another proof to lack of clearly defined ideas concerning the TMJ anatomy, physiology in terms of gender differences, age-related changes, dentofacial system diseases, as well as constitutional (somatotypic) features [6, 35, 41, 51, 55, 58]. Experts claim that the supporting teeth apparatus, the chewing muscles and the TMJ constitute an interconnected functional unit that has stable self-regulation involving all the active components and ensuring effective operation of the entire dentition. The highly coordinated activity of the TMJ elements, taken as a complex anatomical unit, is regulated by the central nervous system through the muscle contractile activity, and is manifested by the balance of the left and right joints, and the presence of not only articulating (rotational) yet also translational movements along with pronounced adaptive & compensatory capacity in the joint [1, 13, 34, 42, 47–49, 54, 57, 60].

The epidemiological studies carried out in Russia reveal that the prevalence of structural and functional pathology of TMJ in the adult population reaches 89.4%, in young people — 61.3%, second only to dental caries and periodontal diseases. Despite the high incidence, TMJ diseases fall within the most complex and poorly studied groups of human pathology, while the respective issues implying improved methods of complex diagnostics, treatment and rehabilitation are extremely urgent and important in modern dentistry [52].

One of the key factors that determines the biochemical body features, and, therefore, the specifics of the constitution (body type), is the mesoderm parenchyma (mesenchyme). Depending on the quality and volume of the connective tissue found in the body, the following constitutional types have been identified (A. Bogomolets, 1926): asthenic — with tender and thin connective tissue dominating; fibrous — featuring the prevalence of dense and fibrous connective

tissue; pasty — with quaggy and edematous connective tissue prevailing; lipomatous — with abundant fat tissue (adipose degeneration). The somatotype is the result of the morphological parameters, which points at a particular body constitution type (Nikityuk B.A., 1995).

Experts have established a close link between the body reactivity, the metabolic intensity, the immune and endocrine status on the one hand, and body type on the other. The introduction of the population-centric somatotyping scheme, which is commonly observed in preventive medicine and clinical practice, is due to the sensitivity in assessing the individual development and the metabolic process rates; the simplicity of the method requiring a minimum number of anthropometric measurements; the proven link between clinically significant features and the somatotype; potential use of an individual-typological approach when analyzing the major values, as well as the established *physiological norm* of signs taking into account the body type and the racial and ethnic background [3–5, 8, 10, 12, 16, 19, 36, 46, 51, 56, 63].

Constitutional morphological diagnostics belongs to the research field of both theoretical and applied medicine. Currently, apart from the conventional anatomical and anthropometric approaches, there are also advanced high-tech research methods available, which allow proper evaluation of individual morphological features. Further research in clinical medicine is to be focused not only on the genetic predisposition in case of certain diseases observed in various morphological body constitutions, yet also on the fact that a particular body type can be viewed as a favorable factor, which may be indicative of a sufficient adjustment potential and lower likelihood of developing certain pathologies [2, 7, 9, 11, 15, 18, 20, 24, 27, 32, 38–40].

TMJ histomorphological studies helped identify five physiological structures (*norms*) (Petrosov Yu.A., 2007). Option one is a combination of a deep mandibular fossa with a well-developed lower jaw head. Option two is a small head of the lower jaw combined with a narrow and deep mandibular fossa. A third option is a combination of a well-developed lower jaw head with a narrow and deep mandibular fossa. Option four implies a small head of the lower jaw combined with a mandibular fossa that is flattened and wide. And another option is a combination of a well-developed lower jaw head with a shallow and wide mandibular fossa. The TMJ type that matches the first option is considered the standard *norm*, while the remaining ones are viewed as potentially sensitive to the development of morphofunctional disorders.

Morphologists and dentists take specific interest in data on the anatomical and topographic structure of

TMJ elements at the stages of the craniofacial complex development. Research literature offers description of the relationship between the position of the lower jaw head and facial morphology. People with a vertical growth type of the facial part have been identified as featuring disturbed position of the lower jaw head much more often than persons with the horizontal growth type [17, 22, 26, 33, 53, 65]. X-ray diagnostic methods analysis indicates that a decrease in the anterior articular space is typical of the vertical type of facial growth, and, on the contrary, an increase in the anterior articular space is to be observed with the vertical type of growth [14, 21, 23, 25, 28, 29, 43–45, 61, 64].

The difficulty studying the temporomandibular joint can be accounted for by its small size, different density of the elements, the proximity to the skull base, later manifestation of clinical and diagnostic symptoms of dysfunction with a long latent period, as well as by low reliability of the methods like tomography, panoramic radiography, orthopantomography, contrast arthrography, which is due to the technology specifics [30, 37].

Employing methods for TMJ visualization using cone beam computed tomography and magnetic resonance imaging taken as advanced, high-tech, precision X-ray diagnostics methods, allows obtaining high-resolution 3D images; identifying the bone and soft tissue element status (articular disc, joint ligaments), as well as to studying their movement through function; conducting densitometric and planimetric studies; registering angular parameters to select proper diagnostics and treatment for patients with congenital and/or acquired maxillofacial pathologies [31].

Research works propose methods for measuring the temporal bone articular fossa and the lower jaw articular heads, which allow estimating the joint space size and the articular head location at different positions of the lower jaw [59, 62]. The available literature offers no account of index values that determine the ratio of the TMJ articular head and articular fossae size in people with physiological occlusion, as well as there is no data on the congruence of the major elements of the joint. Besides, there is no sufficient data on the link between the patient's body type and TMJ individual features, which was the purpose of this present study.

Aim of study:

to identify the linear parameters, the index values of the temporomandibular joint elements in people with the permanent teeth orthognathic bite and different body constitution types.

MATERIALS AND METHODS

A clinical and X-ray examination of the temporomandibular joint was performed involving 297 people

(143 males, 154 females; median age 27.4 ± 2.1) in their first adulthood period, with complete dentition, orthognathic bite, and no sign of muscle & articular dysfunction. Following the age periodization scheme recommended by the VII All-Union Conference on Age Morphology, Physiology and Biochemistry (Moscow, 1965), the first period of adulthood for males is 22–35, while for females it is 21–35.

X-ray methods for the temporomandibular joint examination included panoramic radiography and cone beam computed tomography. The panoramic study was carried out on RayscanSymphonyAlpha 3D X-ray machine (South Korea) in the panoramic shooting software TEMPOROMANDIBULAR JOINT LATERAL PROJECTION (open, closed). The outcomes were processed using RayScanver. 2.0.0.0 offering the option of receiving, processing and storing data in the DICOM3.0-compatible format. The features of the panoramic shooting were: voxel size — 140–230 μm ; magnification — 1.3; sensor — CMOS; focal spot — 0.5 mm; time — 2–14 s; panoramic image size — 148 mm; detector resolution — 630×1024 pixels. We used radiographs to evaluate the temporomandibular joint elements location at different positions of the lower jaw (closing in the usual occlusion, closing with the lower jaw forward, closing with the lower jaw down). Fig. 1 offers a view on the temporomandibular joint radiographs in the lateral projection.

Basic linear dimensions measuring method.

The radiographs of the temporomandibular joint in the lateral projection get marked with the major anthropometric landmarks — the greatest convexity point of the articular tubercle; the point located on the lower edge of the external auditory meatus; the top point of the articular head. Further, the length of the articular fossa (head) was measured — between the greatest convexity points of the articular tubercle and the point located on the lower edge of the external auditory meatus, as well as the height of the articular fossa (head) in the vertical direction — between the articular head upper point and the point shaped by the intersection of the perpendicular and the horizontal lines (Fig. 2).

The computed tomography scanning of the temporomandibular joint was performed on a PaX-i3D SC cone beam tomograph with a FOV cephalostat (17×15 cm) (VATECH Global, South Korea). The results were processed using the following software products: dental graphic program SimPlant (Materialize Dental, Belgium) — for simultaneous viewing of axial, transverse (cross-section), panoramic sections; Viewer™ (Windows) software — for archiving, viewing, and importing data; EzDent-I™ (VATECH) software for

obtaining, processing, storing, and exporting data in the DICOM JPG universal medical file formats; the diagnostic software Ez 3D-I™ (VATECH) — for three-dimensional (3D) and multiplanar reconstruction. Scan parameters — voxel size — 0.12/0.2/0.3 mm; time — 5.9 s in LowDose/UltraLowDose mode; scanning area size (FOV) — 12×9 cm; rotation step — 1 mm; reconstruction step — 1 mm; section thickness — 1 mm (Fig. 3, 4).

We believe that the following should be pointed out as the advantages of cone beam computed tomography with pre-panoramic radiography while studying the temporomandibular joint: precision; reduced radiation exposure; high-definition images of bone articular elements; imaging of bone articular surfaces in all planes; lack of projection distortions and overlays; visualization (in view of the change degree in contrast and brightness) of the hypertrophy signs of the masticatory muscles, which is necessary to establish the muscle involvement in case of dysfunctional disorders. The identified anthropometric marks allowed calculating the index of the articular (mandibular) fossa as a ratio of height to length. In a similar way, the index of the articular head (lower jaw head) was calculated as the ratio of height to length, expressed in per cent. We believe that when dealing with the dependence between the dimensional parameters of the articular head and articular fossa, there is some reasonable research and applied value in assessing the temporomandibular joint. For this purpose, we have proposed a congruency indicator based on the ratio calculation of the joint head module to the joint fossa module. In this case, the module is calculated as the half-sum of the height to the width of the element in question.

The articular fossa module is taken as 100%. In addition, the marked points allow us to measure linear dimensions in absolute terms and, most importantly, to determine relative indicators, among which the articular fossa index appears reasonable. The articular fossa index is a relative value, which does not require scaling of the joint elements regarding absolute values. A computed increase in the radiographs size when calculating the relative index only increases the statistical reliability of the research results. Systematizing the studied anthropometric parameters makes it obvious that the articular fossa index should be used to interpret the research data and prove the reliability of the proposed classification for the articular fossa — dolichotemporal, mesotemporal and brachytemporal.

The assessment of body types was carried out by determining the height-to-weight value (HWV) following the formula below:

$$\text{HWV} = (P / L) \times 100\%;$$

where P is body weight (kg), L is body length (cm).

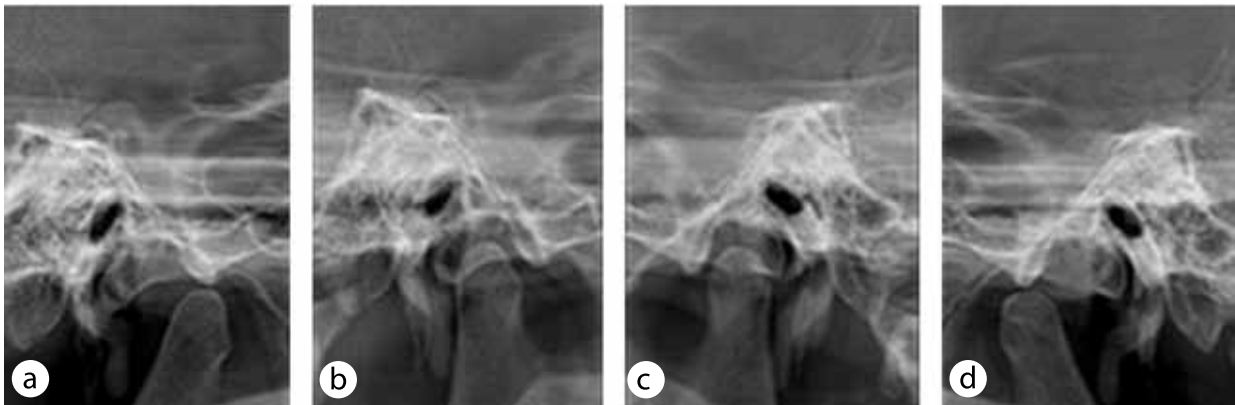


Fig. 1. Temporomandibular joint radiographs in the lateral projection: a — position open to the right, b — position closed to the right, c — position closed to the left, d — position open to the left

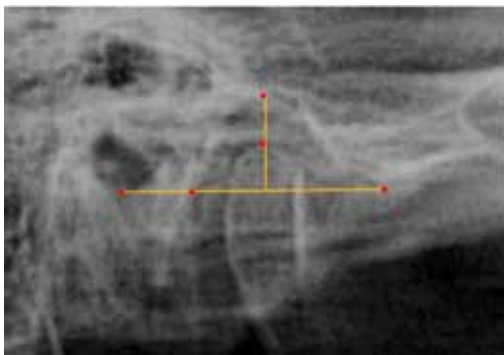


Fig. 2. Measuring the basic linear dimensions on the temporomandibular joint radiograph on the right

The normosthenic (lysomorphic) type of body constitution fell within the HWV values of 37–40%. The asthenic (dolichomorphic) somatotype was identified at HWV value of below 37%, while the hypersthenic (brachymorphic) type was observed at an increase in the HWV beyond the regular values.

For statistical processing of the obtained data, the software products STATISTICA 8.0 and SPSS 22.0 (StatSoft, USA) were used. For each feature, the arithmetic mean value and the arithmetic mean error were identified. When establishing the significance difference between the average values from the counter-lateral sides, the Student t-test was identified. To identify the difference significance between the average parameters through comparing variances, we employed analysis of variance (ANOVA). The value of $p \leq 0.05$ was taken as the critical significance level.

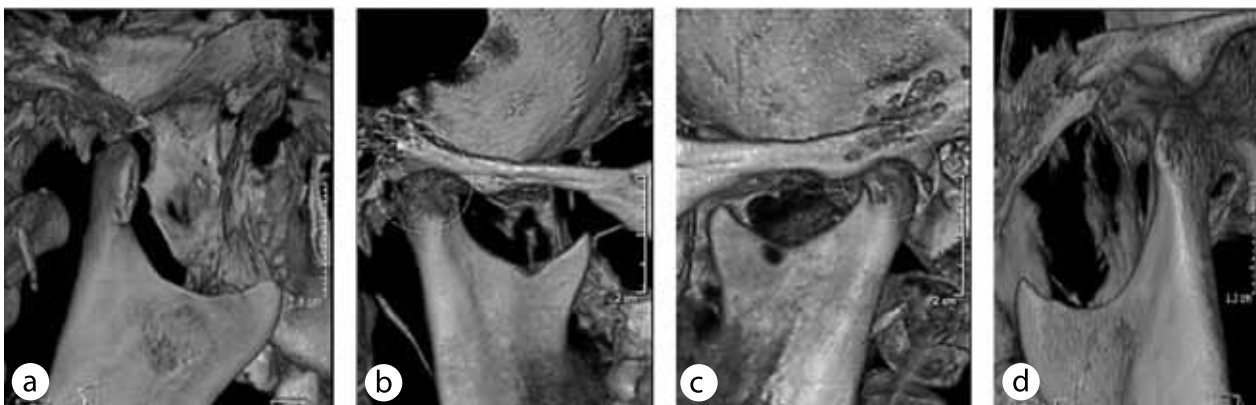


Fig. 3. The temporomandibular joint image obtained through a CT scan in the open position (a — right, d — left) and closed (b — right, c — left)

RESULTS AND DISCUSSION

The preliminary measurements results for the articular fossa in the patients revealed that the average

anteroposterior size was 18.02 ± 0.54 mm; the articular fossa height of the temporal bone was 8.56 ± 0.27 mm, while the average index of the articular fossa was at

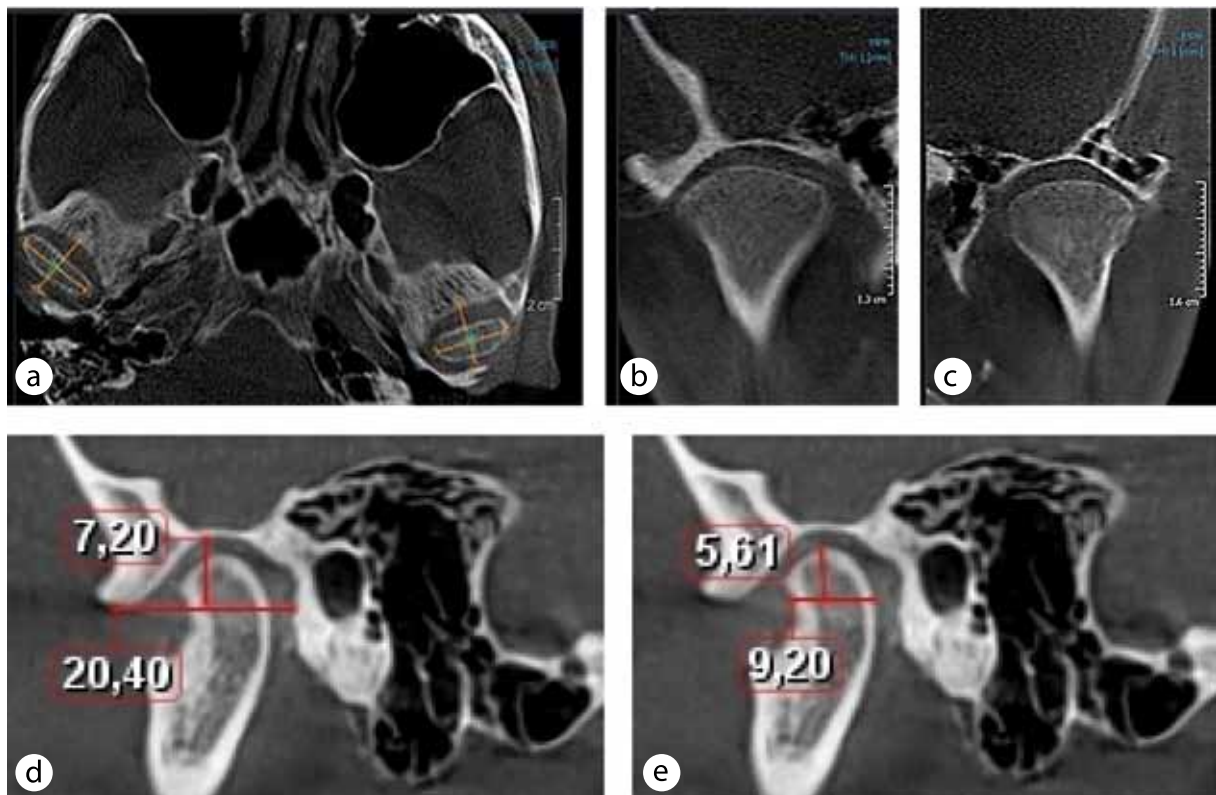


Fig. 4. The temporomandibular joint image in axial (a), coronary right (b), coronary left (c) and sagittal left projections with the mandibular fossa sizes (d) and the lower jaw head (e)

$47.50 \pm 2.08\%$. Given the statistical data in identifying the confidence limits, going beyond the triple of the representativeness error, offered reasonable grounds for division of the articular fossa by the brachy-, meso- or dolicho-temporal type with a probability of 99.7%. In this regard, the articular fossa is equated to the brachytemporal type with an index below 41%, and the dolichotemporal type — with an index above 54%. Therefore, the articular fossa shape in the brachytemporal type is defined as long and low, whereas in the dolichotemporal type — as short and high.

Table 1 contains the morphometric parameters and index values of the major bone elements for various types of the temporomandibular joint.

A comparative assessment of the morphometric parameters and the index values of the bone elements under study (mandibular fossa, the lower jaw head) for various types of TMJ allows us to identify the presence of statistically significant differences based on our classification.

An analysis of the results of the study (Table 1) offers ground to argue that in case of the brachytemporal type of the temporomandibular joint, the mandibular fossa dimensions in the anteroposterior direction prevail over the vertical parameters (Fig. 5).

For patients with the brachytemporal type of the temporomandibular joint, the articular fossa index was $35.29 \pm 1.74\%$, the fossa module was 13.82 ± 0.54 mm, the articular head module was 6.81 ± 0.23 mm, and the congruence was $49.35 \pm 0.77\%$.

In people with the mesotemporal temporomandibular joint, the mandibular fossa parameters in the anteroposterior direction prevail over the vertical dimensions, too. However, the articular fossa index is significantly higher ($48.59 \pm 1.82\%$) than in people with the brachytemporal type ($35.29 \pm 1.74\%$) (Fig. 6).

For patients with the mesotemporal type of the temporomandibular joint, the fossa module was 13.15 ± 0.43 mm, the articular head module was 6.99 ± 0.33 mm, and the congruence was $53.19 \pm 0.89\%$.

In people with the dolichotemporal type of the temporomandibular joint, the articular fossa index ($56.65 \pm 2.12\%$) exceeded the respective values for the brachytemporal ($35.29 \pm 1.74\%$) and mesotemporal ($48.59 \pm 1.82\%$) joint types, which visually defined the joint as *high* and *short* (Fig. 7).

For patients with the dolichotemporal type of the temporomandibular joint, the fossa module

Table 1. Morphometric parameters and index values of the main bone elements for various types of the temporomandibular joint, (M ± m)

Morphometric parameters, index values (units)	Types of temporomandibular joint		
	Brachytemporal	Mesotemporal	Dolichotemporal
Pit Width, (mm)	20,42±0,36*	17,69±0,41	16,01±0,32*
Pit Height, (mm)	7,21±0,89*	8,61±0,55	8,95±0,57*
Pit module, (mm)	13,82±0,54*	13,15±0,43	12,48±0,39*
Fossa index, (%)	35,29±1,74*	48,59±1,82	56,65±2,12*
Head Width, (mm)	8,82±0,31*	9,02±0,44	7,46±0,28*
Head Height, (mm)	4,79±0,19*	4,97±0,51	4,48±0,37*
Head module, (mm)	6,81±0,23*	6,99±0,33	5,97±0,27*
Head Index, (%)	54,42±0,83*	55,09±0,91	60,05±1,37*
Congruence, (%)	49,35±0,77*	53,19±0,89	55,39±0,94*

Note: * — statistically significant in relation to the morphometric parameters and index values of patients with the mesotemporal type of the temporomandibular joint ($p \leq 0.05$).

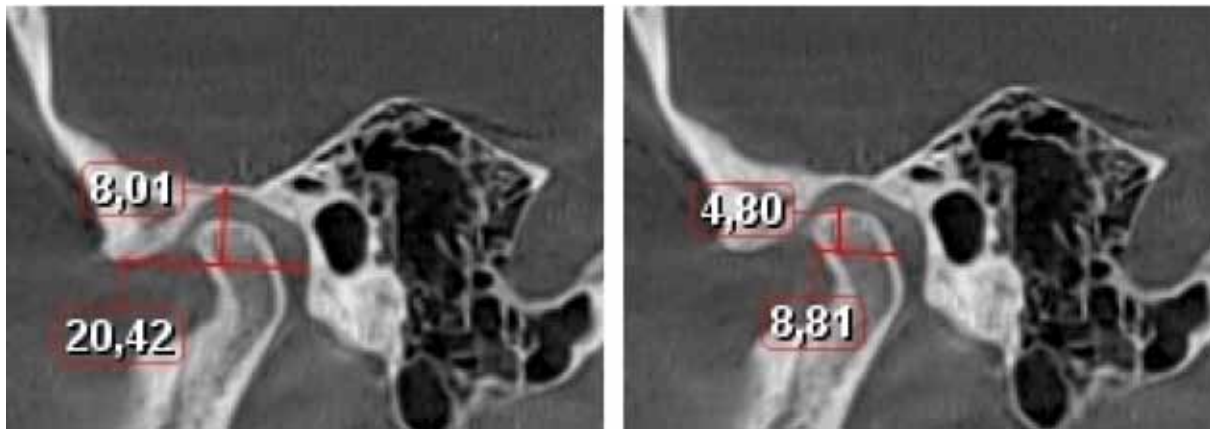


Fig. 5. Brachytemporal temporomandibular joint tomographic image featuring the sizes of the mandibular fossa (a) and of the lower jaw head (b).

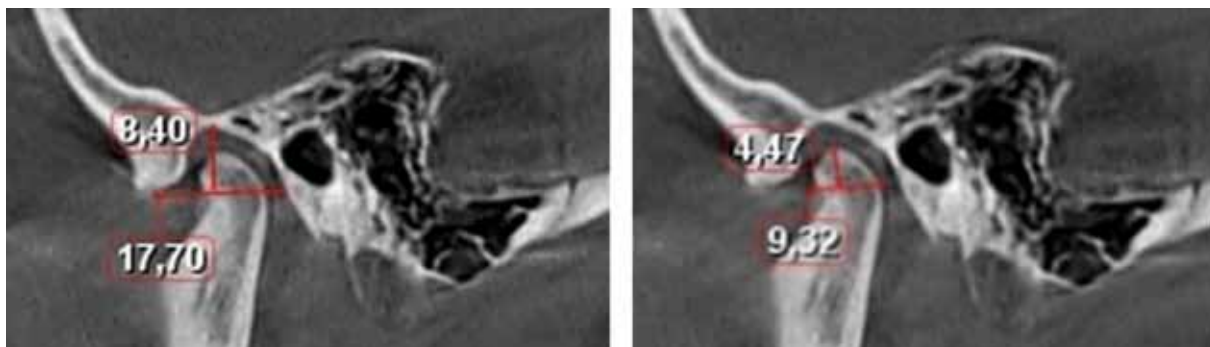


Fig. 6. Tomographic image of the mesotemporal temporomandibular joint with the sizes of the mandibular fossa (a) and the lower jaw head (b).

size was 12.48 ± 0.39 mm, the articular head module was 5.97 ± 0.27 mm, and the congruence value was $55.39 \pm 0.94\%$.

We have proven that in case of physiological occlusion, the studied TMJ morphometric values are statistically significant. There are serious grounds,

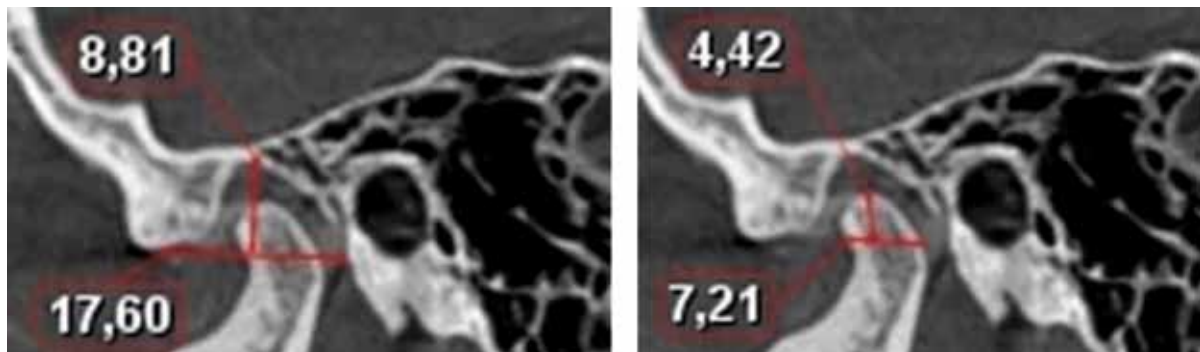


Fig. 7. Tomographic image of the dolichotemporal temporomandibular joint with the size of the mandibular fossa (a) and the lower jaw head (b)

which allow claiming that in case of abnormal (pathological) bites, there are changes occurring not to the articular surface dimensions, yet also extending to the intraarticular topography.

The patients' individual typological differences were distributed as follows: asthenics (dolichomorph body type) accounted for the majority – 168 ($56.6 \pm 4.3\%$) patients; normostenics (lysomorphic constitution type) – 81 ($27.3\% + 2.9\%$) persons; hypersthenics (brachymorphic body type) – 48 ($16.1 \pm 2.3\%$) of the patients examined. Taking into account and identifying the patient's body constitution features will further allow a new perspective when approaching the TMJ morphology issues, identifying predisposing factors in the occurrence of TMJ functional disorders, forecasting the TMJ dysfunction course in the early stages, as well as customizing treatment.

In view of the above, a comparative analysis of the meaning that the X-ray diagnostics methods have for the dentofacial system reveals that panoramic radiography is a reliable method helping visualize the TMJ bone elements status, which also allows identifying pathology (odontogenic, non-odontogenic), as well as related changes in the jaw bone structures. The data obtained through panoramic radiography does not always offer reliable information concerning the TMJ morphology, yet, this method is of high diagnostic value in terms of identifying significant destructive changes in the joint bone components. This is due to the fact that the overlay of the zygomatic arch X-ray image and the skull base on the mandibular (articular) fossa of the temporal bone and the lower jaw articular process on the orthopantomograms complicates significantly the identification of the initial (early) morphological changes in the TMJ bone structures. Unlike panoramic radiographic examination, cone beam computed tomography (through designing multiplanar reconstructions in oblique, sagittal, axial and coronary projections with different slice thickness)

offers proper visualization of the temporomandibular joint bone elements, while the possibility of holding examinations with the mouth closed and open allows reliable evaluation of its functional status.

CONCLUSIONS

1. The proposed methods for measuring the morphometric parameters of the temporomandibular joint with an orthognathic bite, taken as offering precision, high reliability and diagnostically significance, may be recommended for identifying maxillofacial anatomical and topographic features. Each of the methods is of a particular clinical and diagnostic significance, while other calculation methods can be employed as complementary (choice options) at the stage of the comprehensive examination and the tactics choice for treating patients with craniofacial anomalies (deformations), in order to increase efficiency and ensure optimal treatment (rehabilitation) outcomes.
2. The key indicator to classify a temporomandibular joint as belonging to a certain (brachy-, meso-, dolichotemporal) type is the individual feature of the temporal bone mandibular (articular) fossa, which is expressed in linear (absolute) sizes and index (relative) values.
3. For the mesotemporal type of the temporomandibular joint, the articular fossa index varies within 50%, which in linear dimensions indicates a double prevalence of the anteroposterior parameter over the vertical one. In case of the brachytemporal type, a decrease in the vertical size of the articular fossa is observed, which is expressed in the index decrease for the articular fossa (down to 35%). The dolichotemporal type, on the contrary, features an increase in the vertical parameters with a corresponding increase in the articular fossa index values by more than 56%.

4. With the orthognathic bite and a complete set of permanent teeth, there was the size variability of the lower jaw articular heads identified. However, there was no statistically significant difference in the major linear parameters observed. Following the structural options for the lower jaw head shape (according to Yu.A. Gladilin, 1969), oval-shaped heads (171 patients — 57.8%) are more common than cone-shaped (81 people — 27.4%) and bean-shaped (44 people — 14.8%) heads.
5. Regardless of the type (brachy-, meso-, dolichotemporal) of the temporal bone mandibular fossa with the orthognathic bite and a complete set of permanent teeth, the lower jaw head occupies no more than 56% of the joint volume, evidence to that being the temporomandibular joint congruency index.
6. The diagnostic efficiency parameters (sensitivity, specificity, accuracy) of the X-ray diagnostics methods employed to study of the temporomandibular joint structures include: for orthopantomography – 58.3%, 65.9%, 78.4%; for cone beam computed tomography — 93.1%, 95.7%, 94.2%, respectively.
7. Orthopantomography, which allows obtaining a planar image of the dentition elements, is one of the easy-to-perform, affordable, and relatively reliable X-ray diagnostics methods for the temporomandibular joint. Adding cone-beam computed tomography with panoramic radiography can be recommended for checking the preliminary diagnosis and planning the diagnostics and treatment tactics when dealing with patients suffering from temporomandibular joint issues.
8. A significant drawback of panoramic radiography, when examining the temporomandibular joint, is lack of option for obtaining statistically reliable information regarding the spatial relationship of the lower jaw head and the nearest anatomical structures — the temporal bone mandibular (articular) fossa and the articular tubercle.
9. Cone-beam computed tomography, as a specific and highly sensitive method used for spatial diagnostics of morphological, traumatic, degenerative lesions, as well as for changes in the temporomandibular joint bone structures, does not allow full visualization of disorders of the cartilage, muscle and soft tissue components. Due to the polyetiological nature of muscle & joint dysfunction, comprehensive diagnostics should be based on a combined use of computed tomography and magnetic resonance imaging, which would allow obtaining high-quality images of all the temporomandibular joint elements thus helping identify

pathology in the early stages, and design effective pathogenetic schemes for comprehensive treatment.

10. The individual differences detected via X-ray methods in patients with physiological occlusion and various types of temporomandibular joint serve another ground for employing customized values through diagnostics of patients with dentoalveolar anomalies and deformities. There is an obvious need for further detailed and specified study into issues related to constitutionally genetic predisposition that may trigger temporomandibular joint pathology, and it may help identify prognostic factors, increase the efficiency while reducing the treatment time, as well as the risk of negative long-term effects (complications).

REFERENCES

1. **BORODINA V.V., DOMENYUK D.A., WEISHEIM L.D., DMITRIENKO S.V.** Biometry of permanent occlusion dental arches – comparison algorithm for real and design indicators // *Archiv EuroMedica*. 2018. Vol. 8. № 1. P. 25–26.
2. **DAVYDOV B.N., DOMENYUK D.A., DMITRIENKO S.V., KOROBKEEV A.A., ARUTYUNOVA A.G.** Morphological peculiarities of facial skelet structure and clinical and diagnostic approaches to the treatment of dental anomalies in children in the period of early change. *Pediatric dentistry and prophylaxis*. 2019; Vol. 19; 1 (69): 26–38. (In Russ.) DOI: 10.33925/1683-3031-2019-19-69-26-38
3. **DAVYDOV B.N., DOMENYUK D.A., DMITRIENKO S.V.** Peculiarities of microcirculation in periodont tissues in children of key age groups sufficient type 1 diabetes. Part I. *Periodontology*, 2019; Vol. 24; 1–24(90): 4–10. DOI: 10.25636/PMP.1.2019.1.1
4. **DAVYDOV B.N., DOMENYUK D.A., DMITRIENKO S.V.** Peculiarities of microcirculation in periodont tissues in children of key age groups sufficient type 1 diabetes. Part II. *Periodontology*. 2019;24(2):108–119. (In Russ.) DOI:10.33925/1683-3759-2019-24-2-108-119
5. **DAVYDOV B.N., DOMENYUK D.A., BYKOV I.M., IVCHENKO L.G., DMITRIENKO S.V.** Modern possibilities of clinical-laboratory and x-ray research in pre-clinical diagnostics and prediction of the risk of development of periodontal in children with sugar diabetes of the first type. Part I. *Periodontology*, 2018; Vol. 23; 3–23(88): 4–11. DOI:10.25636/PMP.1.2018.3.1
6. Diagnostic Criteria for Temporomandibular Disorders (DC/TMD) for Clinical and Research Application: Recommendations of International RDC/TMD Consortium Network and Orofacial Pain Special Interest Group / Eric L. Schiffman [et al.] // *J. of Oral & Facial Pain And Headache*. – 2014. – N 1. – P. 6–27.
7. **DMITRIENKO S.V., DOMENYUK D.A., MELEKHOV S.V., DOMENYUK S., WEISHEIM L.D.** Analytical approach within cephalometric studies assess-

- ment in people with various somatotypes // *Archiv EuroMedica*. 2019. Vol. 9; 3: 103–111. <https://doi.org/10.35630/2199-885X/2019/9/3.29>
8. **DMITRIENKO S.V., DOMENYUK D.A., VEDESHINA E.G.** Shape individualization in lower dental arches drawn on basic morphometric features // *Archiv EuroMedica*, 2015. Vol. 5. № 1. P. 11.
 9. **DMITRIENKO S.V., DOMENYUK D.A., KOCHKONYAN A.S., KARSLIEVA A.G., DMITRIENKO D.S.** Interrelation between sagittal and transversal sizes of maxillary dental arches // *Archiv EuroMedica*, 2014. Vol. 4. № 2. P. 10–13.
 10. **DMITRIENKO S.V., DOMENYUK D.A., KOCHKONYAN A.S., KARSLIEVA A.G., DMITRIENKO D.S.** Modern classification of dental arches // *Archiv EuroMedica*, 2014. Vol. 4. № 2. P. 14–16.
 11. **DMITRIENKO S.V., DOMENYUK D.A.** Dentoalveolar specifics in children with cleft palate during primary occlusion period. *Archiv EuroMedica*, 2018; Vol. 8; 1: 33–34.
 12. **DMITRIENKO S.V., DOMENYUK D.A., FISCHER S.B., SUBBOTIN R.S.** Dynamics of periodontal fixing capacity through orthodontic treatment employing edgewise technique // *Archiv EuroMedica*. 2019. Vol. 9; 1: 151–152. <https://doi.org/10.35630/2199-885X/2019/9/1/151>
 13. **DMITRIENKO S.V., FOMIN I.V., DOMENYUK D.A., KONDRATYUK A.A., SUBBOTIN R.S.** Enhancement of research method for spatial location of temporomandibular elements and maxillary and mandibular medial incisors // *Archiv EuroMedica*. 2019. T. 9. № 1. P. 38–44. <https://doi.org/10.35630/2199-885X/2019/9/1/38>
 14. **DMITRIENKO T.D., DOMENYUK D.A., PORFYRIADIS M.P., ARUTYUNOVA A.G., Kondratyuk A.A., Subbotin R.S.** Connection between clinical and radiological torque of medial incisor at physiological occlusion // *Archiv EuroMedica*. 2019. Vol. 9. № 1. P. 29–37. <https://doi.org/10.35630/2199-885X/2019/9/1/29>
 15. **DMITRIENKO S.V., DOMENYUK D.A., PUZDYRYOVA M.N.** Manufacturing methods for individual aligners and trainers from thermoplasts and clinical indications for their application // *Archiv EuroMedica*. 2019. Vol. 9; 1: 153–154. <https://doi.org/10.35630/2199-885X/2019/9/1/153>
 16. **DMITRIENKO S.V., LEPILIN A.V., DOMENYUK D.A., KONDRATYUK A.A.** Clinical meaning of methods for identifying variability of mental prominence location // *Archiv EuroMedica*. 2019. Vol. 9; 1: 45–46. <https://doi.org/10.35630/2199-885X/2019/9/1/45>
 17. **DMITRIENKO S.V., DAVYDOV B.N., V.V. SHKARIN, DOMENYUK D.A.** Algorithm for determining the size of artificial teeth by the morphometric parameters of the face in people with full adentia. *Dentistry*. 2018; 97(6): 57–60. DOI – 10.17116/stomat20189706157
 18. **DMITRIENKO S.V., PORFYRIADIS M.P., DOMENYUK D.A., BUDAYCHIEV G.M-A.** Dentoalveolar specifics in children with cleft palate during primary occlusion period // *Archiv EuroMedica*, 2018. Vol. 8. № 1. P. 33–34.
 19. **DOMENYUK D.A., SHKARIN V.V., PORFYRIADIS M.P., DMITRIENKO D.S., DMITRIENKO S.V.** Algorithm for forecasting the shape and size of dent arches front part in case of their deformations and anomalies // *Archiv EuroMedica*, 2017. Vol. 7. № 2. P. 105–110.
 20. **DOMENYUK D.A., ZELENSKY V.A., SAMEDOV F.V., ANFINOGENOVA O.I., KONNOV V.V.** Biochemical aspects of oxidative stress development in children with type 1 diabetes mellitus // *Archives of Pharmacy Practice*. 2019. Vol. 10. № 4. P. 1–9.
 21. **DOMENYUK D.A., DAVYDOV B.N., DMITRIENKO S.V., SUMKINA O.B., BUDAYCHIEV G. M-A.** Changes of the morphological state of tissue of the paradental complex in the dynamics of orthodontic transfer of teeth (experimental study). *Periodontology*, 2018; Vol. 23; 1–23(86): 69-78. DOI:10.25636/PMP.1.2018.1.15
 22. **DOMENYUK D.A., SHKARIN V.V., PORFYRIADIS M.P., DMITRIENKO D.S., DMITRIENKO S.V.** Classification of facial types in view of gnathology // *Archiv EuroMedica*, 2017. Vol. 7. № 1. P. 8–13.
 23. **DOMENYUK D.A., ZELENSKY V.A., RZHEPAKOVSKY I.V., ANFINOGENOVA O.I., PUSHKIN S.V.** Application of laboratory and x-ray general studies un early diagnostics of metabolic disturbances of bone tissue in children with autoimmune diabetes mellitus. *Entomology and Applied Science Letters*. 2018; 5(4): 1–12.
 24. **DOMENYUK D.A., ZELENSKY V.A., DMITRIENKO S.V., ANFINOGENOVA O.I., PUSHKIN S.V.** Peculiarities of phosphorine calcium exchange in the pathogenesis of dental caries in children with diabetes of the first type. *Entomology and Applied Science Letters*. 2018; 5(4): 49–64.
 25. **DOMENYUK D.A., KONNOV V.V., PICHUGINA E.N., ANFINOGENOVA O.I., GONCHARENKO A.N., PUSHKIN S.V.** Microcomputed tomography in qualitative and quantitative evaluation of dental enamel demineralization. *Entomology and Applied Science Letters*. 2018; 5(4): 72–83.
 26. **DOMENYUK D.A., DMITRIENKO S.V. PORFYRIADIS M.P.** Major telerenthenogram indicators in people with various growth types of facial area // *Archiv EuroMedica*. 2018. Vol. 8. № 1. P. 19–24.
 27. **DOMENYUK D.A., SAMEDOV F., DMITRIENKO S.V., ANFINOGENOVA O.I., GLIZHOVA T.N., LYSAN D., NUZHNYAYA CH.** Matrix metalloproteinases and their tissue inhibitors in the pathogenesis of periodontal diseases in type 1 diabetes mellitus // *Archiv EuroMedica*. 2019. Vol. 9. № 3. P. 81–90. <https://doi.org/10.35630/2199-885X/2019/9/3.25>
 28. **DOMENYUK D.A., DAVYDOV B.N.** Possibilities of microcomputer tomography in the diagnostics of early forms of caries of a chewing surface of permanent molars in children. Part I. *Pediatric dentistry and prophylaxis*. 2018; Vol. 18; 4 (67): 61–64. (In Russ.) DOI: 10.25636/PMP.3.2018.4.12

29. DOMENYUK D.A., DAVYDOV B.N. Possibilities of microcomputer tomography in the diagnostics of early forms of caries of a chewing surface of permanent molars in children. Part II. Pediatric dentistry and prophylaxis. 2019; Vol. 19; 2 (70): 4–12. (In Russ.) DOI: 10.33925/1683-3031-2019-19-2-04-12
30. DOMENYUK D. A., KOROBKEEV A. A., DMITRIENKO S. V., KOROBKEEVA YA. A., GRININ V. M., SHKARIN V. V. Anatomical and topographical features of temporomandibular joints in various types of mandibular arches. *Medical News of North Caucasus*. 2019;14(2):363–367. DOI – <http://dx.doi.org/10.14300/mnnc.2019.14089> (In Russ.)
31. DOMENYUK D.A., LEPILIN A.V., FOMIN I.V., DMITRIENKO S.V., BUDAYCHIEV G.M-A. Improving odontometric diagnostics at jaw stone model examination // *Archiv EuroMedica*. 2018. Vol. 8. № 1. P. 34–35.
32. DOMENYUK D.A., PORFYRIADIS M.P., BUDAYCHIEV G. M-A. Contemporary methodological approaches to diagnosing bone tissue disturbances in children with type 1 diabetes. *Archiv EuroMedica*, 2018; 8(2): 71–81.
33. DOMENYUK D.A., VEDESHINA E G., DMITRIENKO S.V. Correlation of dental arch major linear parameters and odontometric indices given physiological occlusion of permanent teeth in various face types // *Archiv EuroMedica*. 2016. Vol. 6. № 2. P. 18–22.
34. DOMENYUK D.A., VEDESHINA E G., DMITRIENKO S.V. Mistakes in Pont (Linder-Hart) method used for diagnosing abnormal dental arches in transversal plane // *Archiv EuroMedica*. 2016. Vol. 6. № 2. P. 23–26.
35. Expanding the taxonomy of the diagnostic criteria for temporomandibular disorders / C. C. Peck [et al.] // *J. of Oral Rehabilitation*. – 2014. – N 1. – P. 1–77.
36. FISCHEV S.B., PUZDYRYOVA M.N., DMITRIENKO S.V., DOMENYUK D.A., KONDRATYUK A.A. Morphological features of dentofacial area in peoples with dental arch issues combined with occlusion anomalies // *Archiv EuroMedica*. 2019. Vol. 9; 1: 162–163. <https://doi.org/10.35630/2199-885X/2019/9/1/162>
37. FOMIN I.V., DMITRIENKO S.V., DOMENYUK D.A., KONDRATYUK A.A., ARUTYUNOVA A. Effect of jaw growth type on dentofacial angle in analyzing lateral telerradiographic images // *Archiv EuroMedica*. 2019. Vol. 9; 1: 136–137. <https://doi.org/10.35630/2199-885X/2019/9/2/136>
38. FOMIN I.V., IVANOV S.YU., DMITRIENKO S.V., DOMENYUK D.A., LEPILIN A.V. Efficiency of osseointegration properties manifestation in dental implants with hydroxyapatite plasma coating // *Archiv EuroMedica*. 2019. Vol. 9; 1: 138–139. <https://doi.org/10.35630/2199-885X/2019/9/2/138>
39. GAVRILOVA O.A., DOMENYUK D.A. Specific features of oral cavity microbiocenosis in children using non-removable orthodontic appliances. *Archiv EuroMedica*, 2018; 8(2): 91–92.
40. GAVRILOVA O.A., DOMENYUK D.A. Microbiological verification for the use of thermoplastics in prosthetic treatment of dentition issues in children. *Archiv EuroMedica*, 2018; 8(2): 88–90.
41. GIRARDOT, R. A. JR. Comparison of condylar position in hyperdivergent and hypodivergent facial skeletal types / R. A. Jr. Girardot [et al.] // *Angle Orthod.* – 2001. – Vol. 71, № 4. – P. 240–246.
42. GREMILLION H.A., KLASSER G.D. (EDS.) *Temporomandibular Disorders: A Translational Approach from Basic Science to Clinical Applicability* // Springer International Publishing AG, 2018. – 218 p.
43. KOROBKEEV A. A., DOMENYUK D. A., SHKARIN V. V., DMITRIENKO S. V., MAZHAROV V. N. Variability of odontometric indices in the aspect of sexual dimorphism. *Medical News of North Caucasus*. 2019;14(1.1):103–107. DOI – <https://doi.org/10.14300/mnnc.2019.14062> (In Russ.)
44. KOROBKEEV A.A., DOMENYUK D.A., SHKARIN V.V., DMITRIENKO S.V. Types of facial heart depth in physiological occlusion. // *Medical news of North Caucasus*. 2018. – Vol. 13. – № 4. – P. 627–630. (In Russ., English abstract). DOI – <https://doi.org/10.14300/mnnc.2018.13122>.
45. KOROBKEEV A.A., DOMENYUK D.A., SHKARIN V.V., DMITRIENKO S.V., WEISHEIM L.D., KONNOV V.V. Anatomical features of the interdependence of the basic parameters of the dental arches of the upper and lower jaws of man. *Medical news of North Caucasus*. 2018. – Vol. 13. – № 1-1. – P. 66–69. (In Russ., English abstract). DOI – <https://doi.org/10.14300/mnnc.2018.13019>
46. KULIKOVA, N.G. Evaluation of the effectiveness of pharmaco-physiotherapeutic treatment of catarrhal gingivitis on the results of the condition of mucosal immunity of oral cavity in women in the postpartum period / N.G. Kulikova, D.A. Domenyuk, V.A. Zelen-sky, A.S. Tkachenko // *Medical news of North Caucasus*. 2017. – Vol. 12. – № 4. – P. 417–421. (In Russ., English abstract). DOI: 10.14300/mnnc.2017.12117.
47. LEPILIN A.V., FOMIN I.V., DOMENYUK D.A., DMITRIENKO S.V., BUDAYCHIEV G.M-A. Diagnostic value of cephalometric parameters at graphic reproduction of tooth dental arches in primary teeth occlusion // *Archiv EuroMedica*, 2018. Vol. 8. № 1. P. 37–38.
48. LEPILIN A.V., DMITRIENKO S.V., DOMENYUK D.A., PUZDYRYOVA M.N., SUBBOTIN R.S. Dependence of stress strain of dental hard tissues and periodontal on horizontal deformation degree // *Archiv EuroMedica*. 2019. Vol. 9; 1: 173–174. <https://doi.org/10.35630/2199-885X/2019/9/1/173>
49. LEPILIN A.V., RAJGORODSKIY YU.M., GRIGORYEVA D.A., EROKINA N.L., BAKHTEEVA G.R., DOMENYUK D.A. Reasoning for the application of violet laser physiotherapy device following surgeries in the oral cavity. *Archiv EuroMedica*, 2018; 8(2): P. 111–114.
50. NIKITYUK B.A. *Integration of knowledge in human sciences (Modern integrative anthropology)*. M.: SportAkademPress. 2010. 440 p (in Russ.).

51. OKESON JEFFREY P. Management of Temporomandibular Disorders and Occlusion // *Quintessence*, 7th Edition. – Mosby, 2012. – 504 p.
52. PERSIN L. Orthodontics. Diagnosis and treatment of dentofacial anomalies and deformities. M.: GEOTAR-Media, 2016. 640 p.
53. PORFYRIADIS M.P., DOMENYUK D.A., ARUTYUNOVA A.G., DMITRIENKO S.V. Scanning electron microscopy and X-ray spectral microanalysis in dental tissue resistance // *Archiv EuroMedica*. 2019. Vol. 9; 1: 177–185. <https://doi.org/10.35630/2199-885X/2019/9/1/177>
54. PORFIRIADIS M.P., DMITRIENKO S.V., DOMENYUK D.A., BUDAYCHIEV G.M-A. Mathematic simulation for upper dental arch in primary teeth occlusion // *Archiv EuroMedica*, 2018. Vol. 8. № 1. P. 36–37.
55. SANDERS A.E., SLADE G.D. Gender modifies effect of perceived stress on orofacial pain symptoms: National Survey of Adult Oral Health // *J. Orofac. Pain*. – 2011. – Vol. 25, N 4. – P. 317–326.
56. SHKARIN V., DOMENYUK D., LEPILIN A., FOMIN I., DMITRIENKO S. Odontometric indices fluctuation in people with physiological occlusion. *Archiv EuroMedica*, 2018; Vol. 8; 1: 12–18.
57. SHKARIN V.V., DOMENYUK D.A., PORFIRIADIS M.P., DMITRIENKO D.S., DMITRIENKO S.V. Mathematical and graphics simulation for individual shape of maxillary dental arch // *Archiv EuroMedica*, 2017. Vol. 7; № 1: 60–65.
58. SHKARIN V.V., PORFIRIADIS M.P., DOMENYUK D.A., DMITRIENKO D.S., DMITRIENKO S.V. Setting reference points for key teeth location in case of abnormal dental arch shape // *Archiv EuroMedica*, 2017. Vol.7; № 2: 111–117.
59. SHKARIN V.V., IVANOV S.YU., DMITRIENKO S.V., DOMENYUK D.A., LEPILIN A.V., DOMENYUK S.D. Morphological specifics of craniofacial complex in people with various types of facial skeleton growth in case of transversal occlusion anomalies // *Archiv EuroMedica*. 2019. Vol. 9; 2: 5–16. <https://doi.org/10.35630/2199-885X/2019/9/2/5>
60. SHKARIN V.V., GRININ V.M., KHALFIN R.A., DMITRIENKO S.V., DOMENYUK D.A. Specific features of transversal and vertical parameters in lower molars crowns at various dental types of arches // *Archiv EuroMedica*. 2019. Vol. 9; 2: 174–181. <https://doi.org/10.35630/2199-885X/2019/9/2/174>
61. SHKARIN V.V., GRININ V.M., KHALFIN R.A., DMITRIENKO S.V., DOMENYUK D.A. Specific features of grinder teeth rotation at physiological occlusion of various gnathic dental arches // *Archiv EuroMedica*. 2019. Vol. 9; 2: 168–173. <https://doi.org/10.35630/2199-885X/2019/9/2/168>
62. SHKARIN V.V., GRININ V.M., KHALFIN R.A., DMITRIENKO S.V., DOMENYUK D.A. Specific features of joint space in patients with physiological occlusion on computed tomogram head image // *Archiv EuroMedica*. 2019. Vol. 9; 2: 182–183. <https://doi.org/10.35630/2199-885X/2019/9/2/182>
63. SHKARIN V.V., GRININ V.M., KHALFIN R.A., DMITRIENKO S.V., DOMENYUK D.A. Specific features of central point location between incisors in people with physiological occlusions // *Archiv EuroMedica*. 2019. Vol. 9; 2: 165–167. <https://doi.org/10.35630/2199-885X/2019/9/2/165>
64. SHKARIN V.V., GRININ V.M., KHALFIN R.A., DMITRIENKO T.D., DOMENYUK D.A., FOMIN I.V. Craniofacial line of telerradiography and its meaning at cephalometry // *Archiv EuroMedica*. 2019. Vol. 9; 2: 84–85. <https://doi.org/10.35630/2199-885X/2019/9/2/84>
65. SHKARIN V.V., DAVYDOV B.N., DOMENYUK D.A., DMITRIENKO S.V. Non-removable arch orthodontic appliances for treating children with congenital maxillofacial pathologies – efficiency evolution // *Archiv EuroMedica*, 2018. Vol. 8. № 1. P. 97–98.