

<http://dx.doi.org/10.35630/2199-885X/2020/10/2>

# INCIDENCE OF OSTEONECROSIS OF THE JAW DUE TO BISPHOSPHONATE TREATMENT IN THE CITY OF CRAIOVA

Octavian Mihnea Petrescu<sup>3,1✉</sup>, Valeriu Marin Şurlin<sup>1,2</sup>   
Munteanu Cristina<sup>1,2</sup>, Adrian Camen<sup>1,2</sup> ,  
Gabriel Sebastian Petrescu<sup>1,2</sup>, Elena Cristina Andrei<sup>1</sup> ,  
Ciobanu George Adrian<sup>2</sup> 

<sup>1</sup> University of Medicine and Pharmacy of Craiova, Romania

<sup>2</sup> Department of general surgery

<sup>3</sup> Department of oral and maxillo-facial surgery

✉ octapetrescu@yahoo.com

**ABSTRACT** — Bisphosphonates have been used for many years worldwide for the treatment of osteoporosis, Paget's disease, but especially for the treatment of various bone density disorders such as tumour formations, bone metastases associated with osteolysis and hypercalcaemia. The effects of bisphosphonates on the bones are due to their action on osteoclasts by inhibiting them. Although the existence of the risk of osteonecrosis of the jaw in patients undergoing bisphosphonate treatment is known, this pathology has been considered very rare for a long period and many times the risk of its occurrence has been ignored. Since the use of bisphosphonates is becoming more prevalent and the duration of such treatment is steadily increasing, the incidence of osteonecroses associated with this treatment is also increasing.

**OBJECTIVE.** The objective of this study is to highlight the fact that the incidence of cases of bisphosphonate-related osteonecrosis of the jaw has been increasing in recent years. **METHODS.** We have carried out a search and analysis of all cases with *osteonecrosis* as main diagnosis in the Oral Maxillo-Facial Surgery Clinic during the period from January 2009 and December 2018.

**RESULTS.** We found 84 patients with osteonecrosis of the jaw following bisphosphonate treatment. Of these, 37 were men and 47 women with an average age of 67 and 59 respectively. There were 26 cases (31%) with incidence in the jaw, 52 cases (62%) with incidence in the mandible, and 6 patients (7%) manifested bilateral osteonecrosis of the jaw. Of these, 20% were on the left side, 36% on the right side and 44% on the median line.

**CONCLUSIONS.** The incidence of bisphosphonate-related osteonecrosis of the jaw is steadily increasing due to the more frequent use of a class of bisphosphonates with a strong impact on the oro-facial bone system.

**KEYWORDS** — Medication-related osteonecrosis of the jaw, osteonecrosis, Bisphosphonates, Tooth extraction, Side effect, oral and maxillofacial surgery, anti-angiogenic.

## INTRODUCTION

Bone metastases are a serious and frequent complication of cancer. Their incidence varies greatly depending on the type of tumour and its location. Thus, the incidence in the case of multiple myeloma is 70–95% [1], while in prostate and breast cancer it is 65–75% [2] and in lung cancer 30–40%. The occurrence of bone metastases in other types of tumours is very low [3].

**Bone metastases** are osteolytic in multiple myeloma, lung cancer and melanomas, osteocondensed in prostate cancer and mixed in breast cancer [3].

The tumour cell migration process from the primary tumour to the bone marrow resulting in the occurrence of bone metastases occurs in several successive stages. Initially, the tumour cells are separated from the primary tumour by migrating through the blood or lymphatic vessels to stop in the capillaries of the target organ, namely the bone marrow. Once in the marrow, tumour cells can enter into a latent state, becoming active many years later, or being able to adapt to the local micro-environment (osteomimicry).

The occurrence of bone metastases results both in the impairment of the osteoclast and osteoblast function resulting in a change in normal equilibrium between the new bone formation and the bone resorption. Thus, the bone-derived growth factors and calcium (Ca<sup>2+</sup>) are eliminated from the bone which, in turn, promotes tumour growth [4].

**Bisphosphonates** are inhibitors of bone demineralization for which reason they are used in the treatment of diseases that associate or cause bone resorption. Bisphosphonates are generally administered per os in osteoporosis and intravenously in patients with bone metastases (secondary to prostate, lung, kidney or breast tumours), as well as in various osteolytic bone pathologies (Paget's disease, multiple myeloma) [3, 5].

Bisphosphonates enter the bone with the help of osteoclasts, for which they have an increased affinity and can remain in the bone for more than 15 years and can be released only with bone destruction during the physiological turnover [6, 7].

Some studies suggest that bisphosphonates, in addition to inhibiting osteolysis, could prevent both the occurrence of bone metastases and the survival of latent tumour cells in the bone marrow. The fact that bisphosphonates may have direct antitumour effects in combination with chemotherapy is not yet scientifically proven [8].

Besides to reducing the risk of bone fracture by inhibiting the osteoclastic activity, other benefits of bisphosphonate treatment include pain reduction in cases of bone metastases and reduction in mortality rates [9].

Side effects of bisphosphonates include atypical femoral fractures, osteonecrosis of the jaw, atrial fibrillation as well as various diseases of the gastrointestinal system (oesophageal ulcer, dysphagia, gastroesophageal reflux, xerostomia, dyspepsia) [9].

The American Association of Oral and Maxillofacial Surgeons (AAOMS) has defined bisphosphonate-induced osteonecrosis as the presence of non-cured maxillary or mandibular bone, exposed to the oral cavity environment, with a lack of healing tendency and persisting for more than eight weeks in patients who were administered treatment with bisphosphonates but who did not have metastases in the maxillary bones and did not receive radiotherapy in this area [10].

Diagnosis is generally clinically put by drawing a thorough anamnesis (which should reveal the presence of the bisphosphonate treatment in antecedents) associated with evidence of bone exposed to the oral environment, generally recommending an orthopantomography (OPG) for a radiological confirmation. It is important to note that in the incipient stages no suggestive radiological changes can be visualized in order to guide the practitioner to a precise diagnosis) [11].

AAOMS has proposed the medication-related osteonecrosis of the jaw (MROJ) as follows:

- Stage 0: Patient who was administered bisphosphonate treatment and without exposed, necrotic bone but with discreet radiological changes.
- Stage 1: exposed, necrotic bone, but without the presence of a symptomatology or infection.
- Stage 2: exposed, necrotic bone, with the presence of a painful symptomatology, erythema with or without the presence of purulent secretions.
- Stage 3: exposed, necrotic bone with the presence of a painful symptomatology and local infection, and the extension of bone necrosis to the basilar edge of the mandible or maxillary sinus, possibly leading to pathological fractures, cutaneous fistulas, oro-nasal or oro-antral (oro-sinusal) communications [12].

The conservative treatment seems to give favourable results in the first stages of the ailment [13].

The osteonecrosis of the jaws is a severe complication of the treatment with bisphosphonates and other resorbable agents [5].

Of the many theories on how osteonecrosis onsets following bisphosphonate administration, there are basically two main theories.

The first relates to the inhibition of bone remodelling by direct action on osteoclasts, and the second theory is based on the inhibition of angiogenesis, in both cases leading to the involution and even loss of blood vessels following the development of the avascular bone necrosis.

Although bisphosphonates and anti-angiogenesis agents increase the risk of occurrence of the osteonecrosis of the jaw, the exact mechanism is not yet known. It is also worth mentioning the fact that the number of elderly people requiring this type of treatment is steadily increasing [14].

#### *Effects of bisphosphonates on osteoclasts*

Recent studies have shown that the prevalence and incidence of bisphosphonate-related osteonecrosis (OB) are low [7, 14].

Bisphosphonates remain for prolonged periods in the bone, more precisely in osteoclasts where they inhibit their activity, leading indirectly to anti-resorptive effects. Also, nitrogen-containing bisphosphonates are known to have much stronger resorptive bone effects [7].

Recent studies have concluded that bisphosphonates, once attached to the bone, can inhibit the growth of cells in the covering mucous membrane [15] as well as the fact that they can induce osteoclast apoptosis by inhibiting pyrophosphate synthase [16]. Thus, it was suggested that this apoptosis could be directly involved in the occurrence of osteonecrosis [17, 18].

Hence, by their effect on osteoclasts, it will result in the bone inability to adapt to local trauma and implicitly in their susceptibility to developing infections and micro-fractures [19,20, 21].

It has also been shown that the presence of unhealed micro-cracks in the bones of patients undergoing bisphosphonate treatment is associated to the onset of osteonecrosis [18, 22, 23].

Several studies have described the presence of infection in bisphosphonate-related osteonecrosis, suggesting the possibility of its participation in the onset and development of osteonecrosis [24, 25, 26].

A recent study has found the presence of anaerobic bacteria specific to the periodontal space microflora in the necrotic bone, also suggesting that an oral cavity infection in association with bisphosphonate treatment could be responsible for the osteonecrosis onset [27].

Thus, *Fusobacterium*, *Actinomyces*, *Bacillus*, *Streptococcus*, *Staphylococcus*, *Seimonas*, *Treponema* and *Candida*, were observed to be frequently present in the osteonecrosis of the jaw, [28] these bacteria being detectable at the bone level prior to its necrosis [29].

For patients being administered bisphosphonate treatment, it is advisable to avoid as much as possible dental extractions or any other intervention on the bone, as many studies show the close relationship between dental extraction and the onset of osteonecrosis [30, 31].

In these patients, it is recommended that treatment administration should be discontinued, whenever possible, for approximately 3 months, before any bone surgery. This interruption is performed strictly by the patient's attending oncologist/endocrinologist upon referral and in collaboration with the surgeon [30].

Although the most optimal time between treatment discontinuation and surgery is not known, it is necessary to assess the benefit/risk ratio for each individual patient. The minimum recommended discontinuation period is 3 months [30].

Since bisphosphonates remain in the bone for a long time (more than 3 months), a discontinuation of treatment for several months would not significantly influence the amount of bisphosphonates in the bone but may positively influence the healing of the area subjected to surgical intervention by avoiding the anti-angiogenic effect of the treatment, thus allowing for healing [30].

In a meta-based study carried out on 1,389 cases and 569,620 examinations, there was found there is a close correlation between the bisphosphonate treatment of cancer patients and the onset of osteonecrosis of the jaw. In this study, the risk of onset of this pathology was 4 times higher in the case of intravenous bisphosphonate treatment versus per os administration [30].

#### *Anti-angiogenic effect of bisphosphonates*

Angiogenesis is a physiological process by which occurrence of new blood vessels takes place out of existing ones [32].

In addition to the effect in bones, several articles have brought up the ability of bisphosphonates to inhibit angiogenesis [33], as well as the possible involvement of this effect in the pathogenesis of the osteonecrosis of the jaw [17, 34, 35].

Thus, following in vitro experiments, direct inhibition of osteogenesis and angiogenesis by bisphosphonates administered in high concentrations in the plasma sampled from various patients was observed [15, 36, 37].

Recently, various articles revealed the role of osteoclasts in angiogenesis [17, 38, 39, 40].

Thus, it can be speculated that the anti-angiogenesis effect of bisphosphonates would be an (indirect) consequence of inhibition of osteoclast activity [41].

Moreover, in an in vivo study, the ability of a bisphosphonate (zoledronate) to inhibit PDGF-BB preosteoclasts has been shown to suppress angiogenesis and osteogenesis [42].

Numerous studies have highlighted the role of osteoblasts in stimulating both osteogenesis and angiogenesis [32, 43, 44, 45, 46].

Thus, the suppression of the generation of angiogenic factors of osteoblasts by bisphosphonates may partially explain the occurrence of osteonecrosis of the jaw, [47] since angiogenesis plays a fundamental role both in bone production and remodelling as well as in the occurrence of tumour metastases and osteonecrosis. [48] Compromising angiogenesis also has a negative effect on local healing after surgical intervention [17].

Another study in animals treated with anti-resorptives showed the presence of a reduced vascular network with the occurrence of apoptosis, oxidative stress and hypoxia at the outbreak of the osteonecrosis [49].

#### *Risk factors associated with osteonecrosis onset*

Risk factors that can negatively influence bone metabolism, favouring the occurrence of bisphosphonate-related osteonecrosis include: local or general infections, advanced age, various bone traumas, dental extraction and concomitant use of anti-angiogenic medication or radio-chemotherapy administration. Of all these factors, most commonly involved in initiating an osteonecrosis outbreak is bone trauma in the form of a dental extraction [8].

Of the local risk factors, the extraction of a single tooth or root, the bone loss, the presence of increased mobility teeth and the lack of healing of a bone exposed wound were associated with a higher risk of occurrence of osteonecrosis [50].

Although osteonecrosis of the jaw may also occur in patients undergoing angiogenesis inhibitor treatment, the most documented cases are those related to treatment for osteoporosis and bone metastases, denosumab and bisphosphonates, respectively. The risk of occurrence increases with duration, dose and frequency of treatment [31, 51, 52].

In the scholarly literature, many other risk factors have been reported in the occurrence and worsening of osteonecrosis, such as: dental or periodontal infections, anaemia, corticosteroids, diabetes, smoking, low immunity and poor oral hygiene [31, 53, 54, 55, 56].

## MATERIALS AND METHODS

We have searched for all cases of *osteonecrosis* as main diagnosis at the Oral and Maxillofacial Surgery Clinic diagnosed between January 2009 and Decem-

ber 2018. All patients who had osteonecrosis without a history of bisphosphonate treatment confirmation were excluded from the study.

### RESULTS AND DISCUSSIONS

In this study, we analysed 84 patients with osteonecrosis of the jaw following bisphosphonate treatment. Of these, 37 were men and 47 women with an average age of 62. The group of men was found older (67 average age) compared to the group of women (59 average age). (Table. 1) (Fig. 1) A number of 52 patients came from the urban area, and 32 from the rural area. (Fig. 2)

Table 1. Mean age of men vs women

Age	Women	Men
Sample size	47	37
Arithmetic mean	59.1915	67.6216
95% CI for the mean	55.7693 to 62.6137	64.7747 to 70.4685
Variance	135.8538	72.9084
Standard deviation	11.6556	8.5386
Standard error of the mean	1.7001	1.4037
F-test for equal variances	P = 0.056	

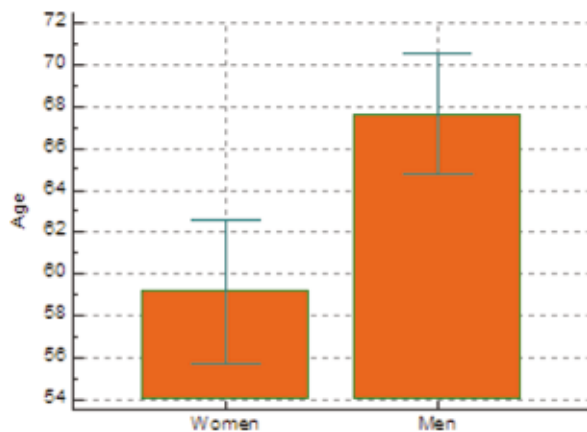


Fig. 1. Women vs Men age

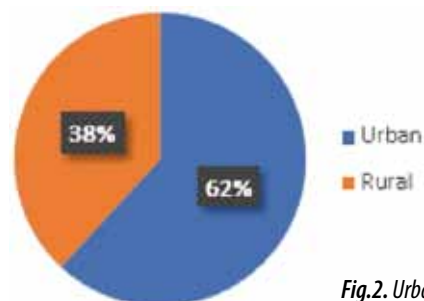


Fig.2. Urban vs Rural

There were 26 (31%) cases of osteonecrosis of the jaw, while 52 (62%) cases of osteonecrosis of the mandible and 6 (7%) patients had bilateral osteonecrosis of the jaw. (Fig. 3) Of these, 20% were on the left side, 36% on the right side and 44% on the median line. (Fig. 4)

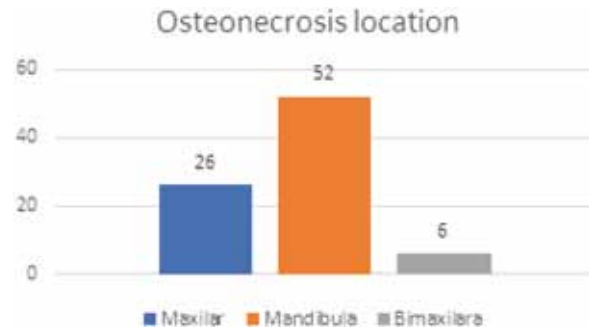


Fig.3. ■ Jaw, ■ Mandible, ■ Bilateral jaw

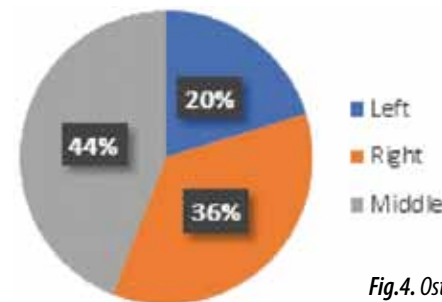
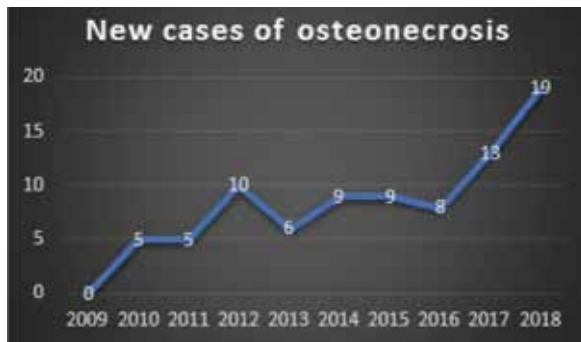


Fig.4. Osteonecrosis location

The main symptomatology that caused patients to come to the doctor was local pain, followed by local changes (denuded bone), as well as physiological disorders caused by oedema and swelling due to the penetration of the germs from the oral environment to the bone left denuded. The patient's delay in presenting to medical examination may lead, in the absence of adequate treatment, to local overinfection, with the appearance of purulent secretions.

The treatment of osteonecrosis included the administration of antibiotics and anti-inflammatory drugs, the local toilette with chlorhexidine and antialgic medication, where needed. Surgery was performed by removing bone seizure only in patients who had a minimum period of 3 months since the last bisphosphonate administration.

In this study, there was an exponential increase in the incidence of the osteonecrosis of the jaw, thus: from 1 new case to 291 admissions, respectively 5 new cases/year in 2010 to 1 new case to 47 admissions, respectively 19 new cases/year in 2018. (Fig. 5)



*Fig.5 Incidence of new cases*

From a clinical point of view, the patients presented in the OMF Polyclinic, being or not being guided here by the dentist, due to the presence of a post-extraction (gingival) injury that did not heal in time, leaving the post-extraction alveolus exposed to the germs in the oral environment. The gum is erythematous, inflamed and associated with local pain, and the underlying bone is exposed, grey, dull, necrotic, with or without local purulent secretions.

Although secondary impairment of the upper gastrointestinal system is considered to be the most common adverse reaction, the bisphosphonate-related osteonecrosis is a condition that once appeared greatly affects the quality of patient's life.

Its incidence is reported in a study to less than 1 in 1,000 patients under per os bisphosphonate treatment [57] and approximately 5% of patients under intravenous treatment to develop osteonecrosis [58], this ailment being very difficult to treat and greatly affecting the quality of patient's life.

Other studies reported an incidence of 0.01–0.06% occurrence of osteonecrosis in patients with per os bisphosphonate administration and 0.8–12% in patients with intravenous bisphosphonate administration [28], thus arguing that the risk of occurrence increases in the case of the intravenous treatment [59].

This was also found in our paper, as most patients were under injectable treatment.

The pathogenesis of osteonecrosis is not yet fully understood, the multiple effects of bisphosphonates on cells could also increase the susceptibility of occurrence of infections and affect the healing of mucous membranes [58], thus leading to the non-closure of the post-extraction alveolus and increasing the risk of germs in the oral cavity infiltrating the bone.

In the current study, all patients who presented complained of the onset of the symptomatology following a dental extraction without performance of

alveolar sutures, and from a clinical point of view the post-extraction site was unhealed.

However, recent statistics show that there is a much greater chance of curing osteonecrosis through surgical intervention compared to simple medical treatment consisting of local administration or systemic antibiotherapy [60, 61].

This is also highlighted in this paper, as all patients were prepared for surgery resulting in a success of approximately 79.76% while another study showed a 76.7% success rate [62].

It is imperative that a relationship be established between the beneficial role of bisphosphonates and the risks of occurrence of osteonecrosis following this treatment before starting any treatment. Thus, explaining to the patient the benefits and risks and possible measures to prevent them is currently the best way to reduce the incidence of osteonecrosis [63].

There is currently no well-established protocol in the treatment of bisphosphonate-related osteonecrosis of the jaw. It is generally recommended to control possible infection followed by a conservative treatment, before surgical treatment.

The conservative treatment plan seeks to maintain proper oral hygiene, to treat dental injuries and periodontal diseases, and to associate local and/or general antibiotic treatment [56].

Conservative treatment seems to be successful in the majority of cases though it can not necessarily reach a complete cure, but it can improve the patient's symptomatology [54, 64].

This is especially recommended for patients who, for various reasons, cannot undergo surgical treatment, for example, when bisphosphonate therapy cannot be discontinued, or when the patient has a contraindication to general anaesthesia.

Some recent studies suggest that dental extractions can be performed in patients treated with bisphosphonates but only under a minor impact on dento-periodontal tissues and under antibiotic protection, suggesting that the osteonecrosis-initiating factor would rather be local infections [65]. This is consistent with our study, in which patients with osteonecrosis asserted lack of pre- or post-extraction antibiotic treatment.

A study by [6] confirms that prophylactic antibiotic administration prior to surgical intervention, associated with appropriate wound closure, can prevent osteonecrosis onset.

According to recent studies, patients treated with per os administered bisphosphonates for the treatment or prevention of osteoporosis did not experience a decrease in the incidence of osteonecrosis in case of discontinuation of the treatment in order to perform

simple dental extractions [50, 66]. In turn, it was found the presence of a late healing of the post-extraction alveolar wound [67, 68] and it is recommended to carry out the extractions only under the conditions of an antibiotic intravenous treatment and the complete closure of the post-extraction alveolus in order to reduce the possibility of infiltration of the germs at bone level [69].

In this study, a preventive discontinuation of bisphosphonate treatment was chosen for 3 months before any intervention was performed, also noticing a delay in healing.

It is noteworthy that any trauma, either chronic or acute, to a bone with a metabolism already altered due to bisphosphonate treatment will further reduce the vascularization of the respective area and implicitly lead to the occurrence of some avascular bone areas which will necrose and thus the onset of bisphosphonate-related osteonecrosis may be initiated following bone trauma.

## CONCLUSION

Although the pathogenesis of the bisphosphonate-related osteonecrosis of the jaw is not fully understood, it is known that a very important role in its occurrence is played by the impairment of both angiogenesis and osteogenesis.

It is recommended to solve any dental problems before any bisphosphonate treatment is set up, maintaining proper oral hygiene and periodic dental examination for early detection of signs of osteonecrosis as well as for professional hygiene. The aim is to avoid as much as possible a surgical intervention involving the bone.

It is very important that any patient who should be treated with bisphosphonates, either to combat osteoporosis or bone metastases, should be made aware of the potential risk (Altınay, Daglı, Altınay, & Altınay, 2019; Damian, Diac, Iov, Hunea, & Bulgaru Iliescu, 2019; Frunzã, 2018; Hosseinpour, 2019) of osteonecrosis of the jaw and be explained the importance of maintaining good oral cavity hygiene in order to prevent the occurrence of this harmful pathology.

It is also important that prior to the application of any dental treatment, the patient informs the physician about bisphosphonate treatment to prevent surgical interventions that may increase the risk of onset of an osteonecrosis outbreak.

The osteonecrosis of the jaws is an ailment secondary to bisphosphonate treatment, but very difficult for both the patient and the physician, which is why it is advisable to prevent this disease occurring before, during and even after the discontinuation of the bisphosphonate treatment.

## Abbreviations

AAOMS = American Association of Oral and Maxillofacial Surgeons; MROJ = medication-related osteonecrosis of the jaw.

## REFERENCES

1. SILVESTRIS F, LOMBARDI L, DE MATTEO M, BRUNO A, DAMMACCO F. Myeloma bone disease: pathogenetic mechanisms and clinical assessment. *Leuk Res.* 2007;31(2):129–38.
2. SOUSA S, CLEZARDIN P. Bone-Targeted Therapies in Cancer-Induced Bone Disease. *Calcif Tissue Int.* 2018;102(2):227–50.
3. MACEDO F, LADEIRA K, PINHO F, SARAIVA N, BONITO N, PINTO L, ET AL. Bone Metastases: An Overview. *Oncol Rev.* 2017;11(1):321.
4. KAN C, VARGAS G, PAPE FL, CLEZARDIN P. Cancer Cell Colonisation in the Bone Microenvironment. *Int J Mol Sci.* 2016;17(10).
5. GAVALDÁ C, BAGÁN JV. Concept, diagnosis and classification of bisphosphonate-associated osteonecrosis of the jaws. A review of the literature. *Med Oral Patol Oral Cir Bucal.* 2016;21(3):e260–70.
6. POXLEITNER P, ENGELHARDT M, SCHMELZEISEN R, VOSS P. The Prevention of Medication-related Osteonecrosis of the Jaw. *Dtsch Arztebl Int.* 2017;114(5):63–9.
7. ENDO Y, KUMAMOTO H, NAKAMURA M, SUGAWARA S, TAKANO-YAMAMOTO T, SASAKI K, ET AL. Underlying Mechanisms and Therapeutic Strategies for Bisphosphonate-Related Osteonecrosis of the Jaw (BRONJ). *Biol Pharm Bull.* 2017;40(6):739–50.
8. COLEMAN R, GNANT M. New results from the use of bisphosphonates in cancer patients. *Curr Opin Support Palliat Care.* 2009;3(3):213–8.
9. REYES C, HITZ M, PRIETO-ALHAMBRA D, ABRAHAMSEN B. Risks and Benefits of Bisphosphonate Therapies. *J Cell Biochem.* 2016;117(1):20–8.
10. Advisory Task Force on Bisphosphonate-Related Osteonecrosis of the Jaws AeAoOaMS. American Association of Oral and Maxillofacial Surgeons position paper on bisphosphonate-related osteonecrosis of the jaws. *J Oral Maxillofac Surg.* 2007;65(3):369–76.
11. ANTONUZZO L, LUNGI A, PETRENI P, BRUGIA M, LAFFI A, GIOMMONI E, ET AL. Osteonecrosis of the Jaw and Angiogenesis inhibitors: A Revival of a Rare but Serious Side Effect. *Curr Med Chem.* 2017;24(28):3068–76.
12. RUGGIERO SL, DODSON TB, FANTASIA J, GOODDAY R, AGHALOO T, MEHROTRA B, ET AL. American Association of Oral and Maxillofacial Surgeons position paper on medication-related osteonecrosis of the jaw--2014 update. *J Oral Maxillofac Surg.* 2014;72(10):1938–56.
13. RAMAGLIA L, GUIDA A, IORIO-SICILIANO V, CUOZZO A, BLASI A, SCULEAN A. Stage-specific therapeutic strategies of medication-related os-

- teonecrosis of the jaws: a systematic review and meta-analysis of the drug suspension protocol. *Clin Oral Investig*. 2018;22(2):597–615.
14. DAMIAN SI, DIAC M, IOV T, HUNEA I, BULGARU ILIESCU D. Particularities of Medical Education in the Field of Forensic Toxicology. Studying Dangerous Chemical Agents in Forensic Research. *Revista Romaneasca pentru Educatie Multidimensionala*. 2019;11(4Sup1):337–344. doi:10.18662/rrem/194
  15. KUROSHIMA S, SASAKI M, SAWASE T. Medication-related Osteonecrosis of the Jaw: A Literature Review. *J Oral Biosci*. 2019.
  16. CORNISH J, BAVA U, CALLON KE, BAI J, NAOT D, REID IR. Bone-bound bisphosphonate inhibits growth of adjacent non-bone cells. *Bone*. 2011;49(4):710–6.
  17. RUSSELL RG. Bisphosphonates: the first 40 years. *Bone*. 2011;49(1):2–19.
  18. ALLEN MR, BURR DB. The pathogenesis of bisphosphonate-related osteonecrosis of the jaw: so many hypotheses, so few data. *J Oral Maxillofac Surg*. 2009;67(5 Suppl):61–70.
  19. ALTINAY F, DAGLI G, ALTINAY M, ALTINAY Z. The role of technology in tourism and health services for accessibility in service management. *Postmodern Openings* 2019; 10(4):1–7. doi:10.18662/po/90
  20. FAVIA G, PILOLLI GP, MAIORANO E. Histologic and histomorphometric features of bisphosphonate-related osteonecrosis of the jaws: an analysis of 31 cases with confocal laser scanning microscopy. *Bone*. 2009;45(3):406–13.
  21. BARON R, FERRARI S, RUSSELL RG. Denosumab and bisphosphonates: different mechanisms of action and effects. *Bone*. 2011;48(4):677–92.
  22. RISTOW O, GERNGROSS C, SCHWAIGER M, HOHLWEG-MAJERT B, KEHL V, JANSEN H, ET AL. Is bone turnover of jawbone and its possible over suppression by bisphosphonates of etiologic importance in pathogenesis of bisphosphonate-related osteonecrosis? *J Oral Maxillofac Surg*. 2014;72(5):903–10.
  23. GONG X, YU W, ZHAO H, SU J, SHENG Q. Skeletal Site-specific Effects of Zoledronate on in vivo Bone Remodeling and in vitro BMSCs Osteogenic Activity. *Sci Rep*. 2017;7:36129.
  24. KIM JW, LANDAYAN ME, LEE JY, TATAD JC, KIM SJ, KIM MR, ET AL. Role of microcracks in the pathogenesis of bisphosphonate-related osteonecrosis of the jaw. *Clin Oral Investig*. 2016;20(8):2251–8.
  25. HOEFERT S, SCHMITZ I, TANNAPFEL A, EUFINGER H. Importance of microcracks in etiology of bisphosphonate-related osteonecrosis of the jaw: a possible pathogenetic model of symptomatic and non-symptomatic osteonecrosis of the jaw based on scanning electron microscopy findings. *Clin Oral Investig*. 2010;14(3):271–84.
  26. KUMAR SK, GORUR A, SCHAUDINN C, SHULER CF, COSTERTON JW, SEDGHIZADEH PP. The role of microbial biofilms in osteonecrosis of the jaw associated with bisphosphonate therapy. *Curr Osteoporos Rep*. 2010;8(1):40–8.
  27. MARX RE, TURSUN R. Suppurative osteomyelitis, bisphosphonate induced osteonecrosis, osteoradionecrosis: a blinded histopathologic comparison and its implications for the mechanism of each disease. *Int J Oral Maxillofac Surg*. 2012;41(3):283–9.
  28. SEDGHIZADEH PP, KUMAR SK, GORUR A, SCHAUDINN C, SHULER CF, COSTERTON JW. Microbial biofilms in osteomyelitis of the jaw and osteonecrosis of the jaw secondary to bisphosphonate therapy. *J Am Dent Assoc*. 2009;140(10):1259–65.
  29. HALLMER F, BJØRNLAND T, ANDERSSON G, BECKTOR JP, KRISTOFFERSEN AK, ENERSEN M. Bacterial diversity in medication-related osteonecrosis of the jaw. *Oral Surg Oral Med Oral Pathol Oral Radiol*. 2017;123(4):436–44.
  30. TAYLOR T, BRYANT C, POPAT S. A study of 225 patients on bisphosphonates presenting to the bisphosphonate clinic at King's College Hospital. *Br Dent J*. 2013;214(7):E18.
  31. NICOLATOU-GALITIS O, RAZIS E, GALITI D, GALITIS E, LABROPOULOS S, TSIMPIDAKIS A, ET AL. Periodontal disease preceding osteonecrosis of the jaw (ONJ) in cancer patients receiving antiresorptives alone or combined with targeted therapies: report of 5 cases and literature review. *Oral Surg Oral Med Oral Pathol Oral Radiol*. 2015;120(6):699–706.
  32. LEE SH, CHAN RC, CHANG SS, TAN YL, CHANG KH, LEE MC, ET AL. Use of bisphosphonates and the risk of osteonecrosis among cancer patients: a systemic review and meta-analysis of the observational studies. *Support Care Cancer*. 2014;22(2):553–60.
  33. ALJOHANI S, FLIEFEL R, IHBE J, KÜHNISCH J, EHRENFELD M, OTTO S. What is the effect of anti-resorptive drugs (ARDs) on the development of medication-related osteonecrosis of the jaw (MRONJ) in osteoporosis patients: A systematic review. *J Craniomaxillofac Surg*. 2017;45(9):1493–502.
  34. LIU C, CUI X, ACKERMANN TM, FLAMINI V, CHEN W, CASTILLO AB. Osteoblast-derived paracrine factors regulate angiogenesis in response to mechanical stimulation. *Integr Biol (Camb)*. 2016;8(7):785–94.
  35. VINCENZI B, NAPOLITANO A, ZOCCOLI A, IULIANI M, PANTANO F, PAPAPIETRO N, ET AL. Serum VEGF levels as predictive marker of bisphosphonate-related osteonecrosis of the jaw. *J Hematol Oncol*. 2012;5:56.
  36. GUARNERI V, MILES D, ROBERT N, DIÉRAS V, GLASPY J, SMITH I, ET AL. Bevacizumab and osteonecrosis of the jaw: incidence and association with bisphosphonate therapy in three large prospective trials in advanced breast cancer. *Breast Cancer Res Treat*. 2010;122(1):181–8.
  37. FANTASIA JE. The Role of Antiangiogenic Therapy in the Development of Osteonecrosis of the Jaw. *Oral Maxillofac Surg Clin North Am*. 2015;27(4):547–53.

38. CARAGLIA M, SANTINI D, MARRA M, VINCENZI B, TONINI G, BUDILLON A. Emerging anti-cancer molecular mechanisms of aminobisphosphonates. *Endocr Relat Cancer*. 2006;13(1):7–26.
39. DE LUCA A, LAMURA L, GALLO M, DANIELE G, D'ALESSIO A, GIORDANO P, ET AL. Pharmacokinetic evaluation of zoledronic acid. *Expert Opin Drug Metab Toxicol*. 2011;7(7):911–8.
40. CACKOWSKI FC, ANDERSON JL, PATRENE KD, CHOKSI RJ, SHAPIRO SD, WINDLE JJ, ET AL. Osteoclasts are important for bone angiogenesis. *Blood*. 2010;115(1):140–9.
41. DRISSI H, SANJAY A. The Multifaceted Osteoclast; Far and Beyond Bone Resorption. *J Cell Biochem*. 2016;117(8):1753–6.
42. CAPPARIELLO A, MAURIZI A, VEERIAH V, TETI A. The Great Beauty of the osteoclast. *Arch Biochem Biophys*. 2014;558:70–8.
43. YIN G, BAI Y, LUO E. Angiogenic suppression of osteoclasts may play a role in developing bisphosphonate-related osteonecrosis of the jaw. *Med Hypotheses*. 2011;76(3):347–9.
44. GAO SY, ZHENG GS, WANG L, LIANG YJ, ZHANG SE, LAO XM, ET AL. Zoledronate suppressed angiogenesis and osteogenesis by inhibiting osteoclasts formation and secretion of PDGF-BB. *PLoS One*. 2017;12(6):e0179248.
45. VEERIAH V, PAONE R, CHATTERJEE S, TETI A, CAPULLI M. Osteoblasts Regulate Angiogenesis in Response to Mechanical Unloading. *Calcif Tissue Int*. 2019;104(3):344–54.
46. HUANG B, WANG W, LI Q, WANG Z, YAN B, ZHANG Z, ET AL. Osteoblasts secrete Cxcl9 to regulate angiogenesis in bone. *Nat Commun*. 2016;7:13885.
47. HU K, OLSEN BR. Osteoblast-derived VEGF regulates osteoblast differentiation and bone formation during bone repair. *J Clin Invest*. 2016;126(2):509–26.
48. BUETTMANN EG, MCKENZIE JA, MIGOTSKY N, SYKES DAW, HU P, YONEDA S, ET AL. VEGFA from Early Osteoblast Lineage Cells (Osterix+) is Required in Mice for Fracture Healing. *J Bone Miner Res*. 2019.
49. ISHTIAQ S, EDWARDS S, SANKARALINGAM A, EVANS BA, ELFORD C, FROST ML, ET AL. The effect of nitrogen containing bisphosphonates, zoledronate and alendronate, on the production of pro-angiogenic factors by osteoblastic cells. *Cytokine*. 2015;71(2):154–60.
50. CHIM SM, TICKNER J, CHOW ST, KUEK V, GUO B, ZHANG G, ET AL. Angiogenic factors in bone local environment. *Cytokine Growth Factor Rev*. 2013;24(3):297–310.
51. GKOUVERIS I, HADAYA D, SOUNDIA A, BEZOUGLAIA O, CHAU Y, DRY SM, ET AL. Vasculature submucosal changes at early stages of osteonecrosis of the jaw (ONJ). *Bone*. 2019;123:234–45.
52. HASEGAWA T, KAWAKITA A, UEDA N, FUNAHARA R, TACHIBANA A, KOBAYASHI M, ET AL. A multicenter retrospective study of the risk factors associated with medication-related osteonecrosis of the jaw after tooth extraction in patients receiving oral bisphosphonate therapy: can primary wound closure and a drug holiday really prevent MRONJ? *Osteoporos Int*. 2017;28(8):2465–73.
53. MORGAN GJ, DAVIES FE, GREGORY WM, COCKS K, BELL SE, SZUBERT AJ, ET AL. First-line treatment with zoledronic acid as compared with clodronic acid in multiple myeloma (MRC Myeloma IX): a randomised controlled trial. *Lancet*. 2010;376(9757):1989–99.
54. STOPECK AT, FIZAZI K, BODY JJ, BROWN JE, CARDUCCI M, DIEL I, ET AL. Safety of long-term denosumab therapy: results from the open label extension phase of two phase 3 studies in patients with metastatic breast and prostate cancer. *Support Care Cancer*. 2016;24(1):447–55.
55. FICARRA G, BENINATI F. Bisphosphonate-related osteonecrosis of the jaws: the point of view of the oral pathologist. *Clin Cases Miner Bone Metab*. 2007;4(1):53–7.
56. SAAD F, BROWN JE, VAN POZNAK C, IBRAHIM T, STEMMER SM, STOPECK AT, ET AL. Incidence, risk factors, and outcomes of osteonecrosis of the jaw: integrated analysis from three blinded active-controlled phase III trials in cancer patients with bone metastases. *Ann Oncol*. 2012;23(5):1341–7.
57. OTTO S, SCHREYER C, HAFNER S, MAST G, EHRENFELD M, STÜRZENBAUM S, ET AL. Bisphosphonate-related osteonecrosis of the jaws - characteristics, risk factors, clinical features, localization and impact on oncological treatment. *J Craniomaxillofac Surg*. 2012;40(4):303–9.
58. KHAN AA, MORRISON A, HANLEY DA, FELSENBURG D, MCCAULEY LK, O'RYAN F, ET AL. Diagnosis and management of osteonecrosis of the jaw: a systematic review and international consensus. *J Bone Miner Res*. 2015;30(1):3–23.
59. ZEBIC L, PATEL V. Preventing medication-related osteonecrosis of the jaw. *BMJ*. 2019;365:11733.
60. REID IR, CORNISH J. Epidemiology and pathogenesis of osteonecrosis of the jaw. *Nat Rev Rheumatol*. 2011;8(2):90–6.
61. GAUDIN E, SEIDEL L, BACEVIC M, ROMPEN E, LAMBERT F. Occurrence and risk indicators of medication-related osteonecrosis of the jaw after dental extraction: a systematic review and meta-analysis. *J Clin Periodontol*. 2015;42(10):922–32.
62. EL-RABBANY M, SGRO A, LAM DK, SHAH PS, AZARPAZHOOH A. Effectiveness of treatments for medication-related osteonecrosis of the jaw: A systematic review and meta-analysis. *J Am Dent Assoc*. 2017;148(8):584-94.e2.
63. SOUTOME S, HAYASHIDA S, FUNAHARA M, SAKAMOTO Y, KOJIMA Y, YANAMOTO S, ET AL. Factors affecting development of medication-related osteonecrosis of the jaw in cancer patients



- receiving high-dose bisphosphonate or denosumab therapy: Is tooth extraction a risk factor? *PLoS One*. 2018;13(7):e0201343.
64. **HAYASHIDA S, SOUTOME S, YANAMOTO S, FUJITA S, HASEGAWA T, KOMORI T, ET AL.** Evaluation of the Treatment Strategies for Medication-Related Osteonecrosis of the Jaws (MRONJ) and the Factors Affecting Treatment Outcome: A Multicenter Retrospective Study with Propensity Score Matching Analysis. *J Bone Miner Res*. 2017;32(10):2022–9.
65. **FRUNZĂ, A.** Theoretical Perspectives on the Development of Social Welfare Practice Supervision. *Logos Universality Mentality Education Novelty: Social Sciences*. 2018;7(2):36–54. doi:10.18662/lumenss/08
66. **OTTO S, PAUTKE C, VAN DEN WYNGAERT T, NIEPEL D, SCHIÖDT M.** Medication-related osteonecrosis of the jaw: Prevention, diagnosis and management in patients with cancer and bone metastases. *Cancer Treat Rev*. 2018;69:177–87.
67. **MORETTI F, PELLICIONI GA, MONTEBUGNOLI L, MARCHETTI C.** A prospective clinical trial for assessing the efficacy of a minimally invasive protocol in patients with bisphosphonate-associated osteonecrosis of the jaws. *Oral Surg Oral Med Oral Pathol Oral Radiol Endod*. 2011;112(6):777–82.
68. **OTTO S, TRÖLTZSCH M, JAMBROVIC V, PANYA S, PROBST F, RISTOW O, ET AL.** Tooth extraction in patients receiving oral or intravenous bisphosphonate administration: A trigger for BRONJ development? *J Craniomaxillofac Surg*. 2015;43(6):847–54.
69. **HASEGAWA T, HAYASHIDA S, KONDO E, TAKEDA Y, MIYAMOTO H, KAWAOKA Y, ET AL.** Medication-related osteonecrosis of the jaw after tooth extraction in cancer patients: a multicenter retrospective study. *Osteoporos Int*. 2019;30(1):231–9.
70. **HASEGAWA T, RI S, UMEDA M, KOMATSUBARA H, KOBAYASHI M, SHIGETA T, ET AL.** The observational study of delayed wound healing after tooth extraction in patients receiving oral bisphosphonate therapy. *J Craniomaxillofac Surg*. 2013;41(7):558–63.
71. **HOSSEINPOUR, S.** A comparative study of emotional dimensions of personality in stimulants and opioids users. *BRAIN. Broad Research in Artificial Intelligence and Neuroscience* 2019;10(4):28–39. doi:http://dx.doi.org/10.18662/brain/03
72. **SHUDO A, KISHIMOTO H, TAKAOKA K, NOGUCHI K.** Long-term oral bisphosphonates delay healing after tooth extraction: a single institutional prospective study. *Osteoporos Int*. 2018;29(10):2315–21.
73. **MATSUMOTO A, SASAKI M, SCHMELZEISEN R, OYAMA Y, MORI Y, VOSS PJ.** Primary wound closure after tooth extraction for prevention of medication-related osteonecrosis of the jaw in patients under denosumab. *Clin Oral Investig*. 2017;21(1):127–34.