

<http://dx.doi.org/10.35630/2199-885X/2020/10/4.14>

HISTOMORPHOLOGICAL ALTERATIONS IN THE LUNGS IN ACUTE COMBINED BACLOFEN AND ETHANOL POISONING

Received 27 October 2020;
Received in revised form 20 November 2020;
Accepted 23 November 2020

Olga Romanova^{1,2✉} , **Dmitriy Sundukov**¹ ,
Arkady Golubev^{1,2} , **Mikhail Blagonravov**¹ ,
Evgeniy Barinov^{1,3} , **Alexey Churilov**² ,
Anton Ershov^{2,4} 

¹ RUDN University (Peoples' Friendship University of Russia), Moscow;

² Federal Research and Clinical Center of Intensive Care Medicine and Rehabilitation, Moscow;

³ Yevdokimov Moscow State University of Medicine and Dentistry, Moscow;

⁴ First Medical Sechenov University, Moscow, Russia

✉ olgpharm@yandex.ru

ABSTRACT — A generic Baclofen, also known under the brand name of Lioresal, is a derivative of gamma-aminobutyric acid. Due to its psychotropic effect it is often used as a drug of abuse and for criminal poisoning. An experimental study was carried out on 5 Wistar rats (versus 5 intact rats of the control group) exposed to combined Baclofen (at a dose of 85 mg/kg) and ethanol (7 ml/kg of 40% ethanol) poisoning. We have identified a complex of pathological changes in the lungs of the rats in the early period after the experiment. The outcomes included circulatory disorders of the pulmonary microvasculature (plethora of capillaries, venules), emphysema, atelectasis and dystelectasis, infiltration of white blood cells into intraalveolar septa and thickening of intraalveolar septa due to edema. To quantify the severity of histomorphological changes in the lungs a morphometric study is required.

KEYWORDS — Baclofen, ethanol, poisoning, lungs, histomorphological changes.

BACKGROUND

Baclofen known under the brand name Lioresal is a myorelaxant [1, 2]. This drug is a derivative of gamma-aminobutyric acid and an agonist of GABA (specifically the GABAB) receptors [3, 4].

Baclofen is available in oral and intrathecal forms [1]. The indications to the drug are as follows: multiple sclerosis, muscular spasticity, some spinal cord diseases, such as tumors, infectious diseases, injuries, acute disorders of cerebral circulation, meningitis [2]. Baclofen has been shown to be effective in the treatment of alcohol addicts [5–10] and patients with cerebral palsy [11].

Adverse effects of Baclofen may include headache, drowsiness, dizziness, weakness, fatigue, nausea and vomiting, urinary retention, constipation [3].

Baclofen has a psychoactive effect and can be a subject to abuse in drug addicts, especially in young people [12]. They often use Baclofen with alcohol drinks. Acute combined Baclofen and ethanol poisonings can be a result of an accidental overdose, criminal actions, or suicidal behavior.

The lung is known to be a target organ in such intoxications. At the same time, the data on morphological changes in such poisoning is limited.

The objective of the study

was to assess histomorphological changes in the lungs in acute combined Baclofen and ethanol poisoning 3 hours after the administration.

MATERIAL AND METHODS

Experimental studies were performed on 10 Wistar rats. The animals were divided into 2 groups (the controls and the experimental group). The controls included 5 intact rats. The experimental group included 5 animals treated with Baclofen at a dosage of 85 mg/kg and ethanol (7 ml/kg 40%).

Keeping animals and working with them were carried out in accordance with the European Convention for the protection of vertebrates used for experiments or other scientific purposes (Strasbourg, 18.03.1986).

The lungs were fixed in 10% neutral formalin and immersed into paraffin. Histological sections were processed according to the standard method and stained with hematoxylin and eosin. They were examined by light microscopy using Nikon Eclipse E-400 microscope with a video system based on the Wattec 221S camera (Japan) at 400× magnification.

The signs assessed were as follows: emphysema, atelectasis and dystelectasis, thickening of the interalveolar septa due to edema, WBC infiltration of the interalveolar septa, capillary and venous plethora, sludge, hemorrhages in the interalveolar septa and alveoli, the presence of secretion in the lumen of the bronchi.

In order to confirm the reliability of the appearance of a particular histological sign, we used the Fischer ratio. The presence of a histological sign was

considered to be reliable if it did not appear in any cases in one group and appeared in 4 or 5 cases in the other.

RESULTS AND DISCUSSION

No pathological changes were observed in the lungs of the controls. The alveoli were intact, airy. There were small areas of dystelectasis, located subpleurally. There were no signs of emphysema. Circulatory disorders such as venous, capillary plethora, hemorrhages in the interalveolar septa and alveoli were not observed either. The lumen of the bronchi was free.

In the lungs of the animals treated with the combination of Baclofen (at a dose of 85 mg/kg) and ethanol (7 ml/kg of 40% ethanol) the lumen of the alveoli was free, not expanded. Small areas of emphysema located mainly subpleurally were observed. A large number of areas of dystelectasis was found (Fig. 1).

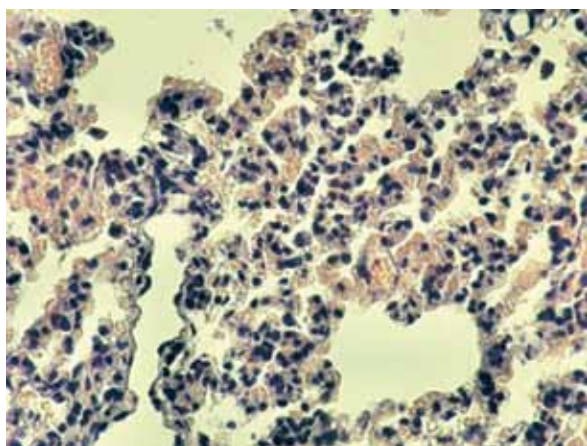


Fig. 1. Baclofen (85 mg/kg)+ethanol (7 ml/kg 40%). Lung of rat. Dystelectasis. Hematoxylin, eosin. Magnification 400

A large cluster of macrophages was observed in the lumen of the alveoli. No sludge was observed in the pulmonary arteries. All intraalveolar septi were infiltrated with WBCs. There was secretion in the lumen of some bronchioles. Thickening of the interalveolar septi due to edema was observed.

Baclofen is known not to have a direct toxic effect on the bronchi and the lungs. However, this drug increases the presynaptic blockade of nerve impulses generated in the spinal cord, which causes suppression of their transmission. As a result, muscular relaxation, including relaxation of respiratory muscles, occurs. This may lead to difficult breathing and hypoxia. The effects of a GABA receptors stimulation on smooth muscles of the bronchi and on the lungs are also of

great importance. Stimulation of GABAA receptors causes contraction of smooth muscles of the bronchi, bronchioles, which is accompanied by spasm and breathing difficulties [13, 14]. Baclofen selectively stimulates GABAB receptors but in high doses it causes GABAA receptor stimulation as well. We observed this effect in the study group. Emphysema was observed in the lungs of the animals. Vascular-tissue permeability increases under hypoxia. According to the literature vascular-tissue permeability increases when GABA receptors are stimulated [15], which is also confirmed by the results of our studies. Thickening of interalveolar partitions due to edema was observed in the experimental group.

CONCLUSION

As a result of the study we identified a complex of pathological changes in the lungs of the rats in the early period after combined Baclofen and ethanol administration, which included circulatory disorders in all the elements of the microcirculatory bed (plethora of capillaries, venules), emphysema, atelectasis and dystelectasis, WBC infiltration into intraalveolar septa and thickening of intraalveolar septa due to edema. To quantify the severity of histomorphological changes in the lungs a morphometric study is required.

REFERENCES

1. Baclofen Monograph for Professionals. Drugs.com. American Society of Health-System Pharmacists. Retrieved 3 March 2019.
2. Gablofen (Baclofen) FDA Full Prescribing Information. US Food and Drug Administration. Retrieved 2016-01-2
3. YOGESWARI P., RAGAVENDRAN J.V., SRIRAM D. An update on GABA analogs for CNS drug discovery. Recent patents on CNS drug discovery. 2006; 1 (1): 113–118. PMID 18221197. DOI:10.2174/157488906775245291.
4. CARTER L.P., KOEK W., FRANCE C.P. Behavioral analyses of GHB: Receptor mechanisms. *Pharmacol. Ther.*, 2008; 121(1): 100–114. DOI:10.1016/j.pharmthera.2008.10.0031.
5. REYNAUD M., AUBIN H-J., TRINQUET F., ZAKINE B., DANO C., DEMATTEIS M., TROJAK B., PAILLE F., DETILLEUX M. A randomized, placebo-controlled study of high-dose baclofen in alcohol-dependent patients—the ALPADIR study. *Alcohol Alcohol.* 2017; 52:439–446. PMID: 28525555 DOI: 10.1093/alcalc/agx030
6. GIRISH K., VIKRAM REDDY K., PANDIT L.V., PUNDARIKAKSHA H.P., VIJENDRA R., VASUNDARA K., MANJUNATHA R., NAGRAJ M., SHRUTHI R. A randomized, open-label, standard controlled, parallel group study of efficacy and safety of baclofen, and chlordiazepoxide in uncomplicated alcohol withdrawal syndrome. *Biomed J.* 2016; 39(1): 72–80.

- DOI: 10.1016/j.bj.2015.09.002. PMID:27105601
PMCID:PMC6138810
7. MÜLLER C.A., GEISEL O., PELZ P., HIGL V., KRÜGER J., STICKEL A., BECK A., WERNECKE K.D., HELLWEG R., HEINZ A. High-dose baclofen for the treatment of alcohol dependence (BACLAD study): a randomized, placebo-controlled trial. *Eur Neuropsychopharmacol.* 2015; 25:1167–1177. PMID:26048580 DOI: 10.1016/j.euroneuro.2015.04.002
 8. MINOZZI S., SAULLE R., RÖSNER S. Baclofen for alcohol use disorder. *Cochrane Database Syst Rev.* 2018;11:CD012557. PMID: 30484285 PMCID: PMC6517285 DOI: 10.1002/14651858.CD012557.pub2
 9. VAN DEN BRINK W. Baclofen: A Game Changer in the Treatment of Alcohol Dependence. *Alcohol Alcohol.* 2020 Feb 7;55(1):46–47. DOI: 10.1093/alcag/agz085. PMID:32031207
 10. VOUREC'H M., FEUILLET F., MAHE P.-J., SEBILLE V., ASEHNOUNE K., BACLOREA trial group. Baclofen to Prevent Agitation in Alcohol-Addicted Patients in the ICU: Study Protocol for a Randomised Controlled Trial. *Trials* 2016; 17 (1): 415 PMID: 27542731 PMCID: PMC4992221 DOI: 10.1186/s13063-016-1539-2
 11. McLAUGHLIN M.J., HE Y., BRUNSTROM-HERNANDEZ J., THIO L.L., CARLETON B.C., ROSS C.J.D., GAEDIGK A., LEWANDOWSKI A., DAI H., JUSKO W.J., LEEDER J.S. Response in Children With Cerebral Palsy *PM R.* 2018;10(3): 235–243. DOI: 10.1016/j.pmrj.2017.08.441.
 12. WEISSHAAR G.F., HOEMBERG M., BENDER K., BANGEN U., HERKENRATH P., EIFINGER F., ROTH-SCHILD M., ROTH B., OBERTHUER A. Baclofen intoxication: a "fun drug" causing deep coma and non-convulsive status epilepticus – a case report and review of the literature. *Eur J Pediatr.* 2012;171(10):1541–7 PMID: 22729246; DOI:10.1007/s00431-012-1780-y
 13. MIZUTA K., XU D., PAN Y., COMAS G., SONETT J.R., ZHANG Y., PANETTIERI JR. R.A., YANG J., EMALA SR C.W. GABAA receptors are expressed and facilitate relaxation in airway smooth muscle. *Am J Physiol Lung Cell Mol Physiol.* 2008;294(6):L1206–16. PMID:18408071
 14. CHAPMAN R.W., HEY J.A., RIZZO C.A., BOLSER D.C. GABAB receptors in the lung. *Trends in pharmacological sciences.* 1993;14(1):26–9. PMID:8382886
 15. DENORA N, LAQUINTANA V, LOPEDOTA A, SERRA M, DAZZI L, BIGGIO G, PAL D., MITRA A.K., LATROFA A., TRAPANI G., LISO G. Novel L-Dopa and dopamine prodrugs containing a 2-phenyl-imidazopyridine moiety. *Pharm Res.* 2007;24(7):1309–24. PMID:17404814